119 B Cell Lymphomas of the Skin

Lorenzo Cerroni and Isabella Fried

Synonyms: ■ Cutaneous B cell lymphomas ■ *S*kin-*a*ssociated *l*ymphoid *t*issue (SALT)-related B cell lymphomas

Key features

- Cutaneous B cell lymphomas represent a group of lymphomas whose primary site is the skin; they are derived from B lymphocytes in different stages of differentiation. The skin can also be the site of secondary involvement by extracutaneous (usually nodal) B cell lymphomas
- Most primary cutaneous B cell lymphomas (>80%) are low-grade malignancies, and they are characterized by indolent behavior and a good prognosis
- Precise classification can be achieved only after a complete synthesis of clinical, histopathologic, immunophenotypic, and molecular features. The WHO-EORTC and ICC classifications provide the basis for a consistent classification of patients
- Treatment options for low-grade types include primarily "watchful waiting", intralesional corticosteroids and local radiotherapy; when solitary lesions are present, surgical excision is an option. Systemic or intralesional anti-CD20 antibody may be used in some patients, while systemic chemotherapy is only required in patients with high-grade tumors

CLASSIFICATION OF B CELL LYMPHOMAS WITH PRIMARY CUTANEOUS MANIFESTATIONS	
WHO-EORTC 2018	**ICC 2022**
• Primary cutaneous follicle center lymphoma	• Primary cutaneous follicle center lymphoma
• Primary cutaneous marginal zone B cell lymphoma*	• Primary cutaneous marginal zone lymphoproliferative disorder
• Primary cutaneous diffuse large B cell lymphoma, leg type	• Primary cutaneous diffuse large B cell lymphoma, leg type
• Primary cutaneous diffuse large B cell lymphoma, other	• Diffuse large B cell lymphoma, NOS
• EBV$^+$ mucocutaneous ulcer (provisional)	• EBV$^+$ mucocutaneous ulcer
• Intravascular diffuse large B cell lymphoma	• Intravascular diffuse large B cell lymphoma
*Includes cases previously designated as primary cutaneous immunocytoma and primary cutaneous plasmacytoma.	

Table 119.1 Classification of B cell lymphomas with primary cutaneous manifestations – WHO-EORTC 2018 and ICC 2022. EBV, Epstein–Barr virus; ICC, International Consensus Classification; NOS, not otherwise specified.

INTRODUCTION

Although B cell lymphomas represent the majority of non-Hodgkin lymphomas (NHLs) arising within *lymph nodes*, they represent a minority of the NHLs whose primary site is the *skin*. In the classification of cutaneous lymphomas published by the World Health Organization (WHO) and the European Organization for Research and Treatment of Cancer (EORTC) Cutaneous Lymphoma Project Group (Table 119.1), B cell lymphomas represented ~25% of all cutaneous lymphomas[1]. The WHO-EORTC classifications of 2005 and 2018 have been integrated with only minor changes into the International Consensus Classification (ICC) of Mature Lymphoid Neoplasms published in 2022 (see Table 119.1)[2,3].

Primary cutaneous lymphomas are defined as *malignant lymphomas confined to the skin at presentation after complete staging procedures*[1,4]. In general, most patients with primary cutaneous B cell lymphoma (pCBCL) are diagnosed by dermatologists, as extracutaneous symptoms and signs are observed only very rarely at the onset of the disease. Consequently, dermatologists should be conversant with the clinicopathologic features of this group of diseases, in order to be able to establish the diagnosis in its early stages. Additionally, as aggressive treatment modalities are needed only in selected cases, these patients should be managed primarily by dermatologists with special expertise in cutaneous lymphomas.

HISTORY

In the past, cutaneous B cell lymphomas were thought to be invariably secondary, that is, due to dissemination of extracutaneous (usually nodal) B cell lymphomas to the skin. In the 1980s, it was recognized that B cell lymphomas whose primary site is the skin, i.e. pCBCLs, represent a distinct group of extranodal lymphomas[4]. The widespread use of immunohistochemical and molecular genetic techniques that can establish clonality, in particular the detection of rearrangements of immunoglobulin genes by PCR (utilizing routine biopsy samples), has shown that some of the cases previously classified as cutaneous B cell pseudolymphomas harbor a monoclonal population of lymphocytes, thus representing low-grade malignant B cell lymphomas of the skin[4,5].

EPIDEMIOLOGY

For the past several decades, the incidence of pCBCL had been rising, but now appears to have stabilized[6]. pCBCLs may occur more frequently in specific regions of the world. For example, analysis of data from four academic centers in the US showed that they represented only 4.5% of all the cases of primary cutaneous lymphoma registered in those centers[7]. In contrast, pCBCL represented ~25% of all the cases of primary cutaneous lymphoma in the Dutch and Austrian registries for cutaneous lymphomas[1].

Regional variations have also been observed with regard to the incidence of specific types of pCBCL. In the two largest series published to date, the relative frequencies of follicle center lymphoma and marginal zone lymphoma varied considerably. Follicle center lymphoma represented 71% of all pCBCLs in the Netherlands, but only 41% in Graz; conversely, marginal zone lymphoproliferative disorder (at that time classified as lymphoma) represented 42% of all cases of pCBCL in Graz, but only 10% in the Netherlands. On the other hand, the relative frequency of the third most common type of pCBCL, the diffuse large B cell lymphoma, leg type, was similar in the two series (~15%), indicating that, in these two series, differences in the relative frequencies were confined to B cell lymphomas characterized by an indolent behavior. This suggests that these variations may be due, at least in part, to a different classification of patients in different centers.

In addition to differences in diagnostic and classification standards, true regional variations in the incidence of special types of pCBCL may be due to the presence of different etiologic factors. For example, the association between pCBCL and infection with specific *Borrelia* subspecies in endemic areas has been known for many years (see below and Ch. 74). This association may explain, in part, regional differences in the incidence of pCBCLs, but the relatively low percentage of such cases (even in countries with endemic *Borrelia* infections) suggests that other etiologies are also involved in regional variations.

pCBCL affects adults of both sexes. With the exception of precursor B lymphoblastic lymphoma/leukemia (which only rarely represents an example of true pCBCL), CBCLs are uncommon in children and adolescents.

Downloaded for Anonymous User (n/a) at Egyptian Knowledge Bank from ClinicalKey.com by Elsevier on March 10, 2024. For personal use only. No other uses without permission. Copyright ©2024. Elsevier Inc. All rights reserved.

ETIOLOGY AND PATHOGENESIS

The pathogenesis of pCBCL is unknown. In contrast to the many nodal B cell lymphomas that have been linked to specific genetic alterations (e.g. nodal follicular lymphomas and interchromosomal 14;18 translocations), there are relatively limited data on the specific genetic features of pCBCLs, especially for low-grade subtypes (for details see below).

Some similarities to the clinicopathologic features observed in B cell lymphomas arising in the gastric mucosa (so-called *mucosa-associated lymphoid tissue* [MALT] lymphomas) led to the hypothesis that pCBCLs are caused by longstanding antigenic stimulation, possibly due to chronic infection with specific microorganisms. In fact, it has been long established that MALT lymphomas originating in the stomach are linked to chronic antigenic stimulation due to infection with *Helicobacter pylori*. As previously mentioned, *Borrelia* spp. are thought to play an etiologic role in a minority of cases of pCBCL, particularly in Europe. In patients from a region in Austria with endemic *Borrelia* infections, specific DNA sequences of *Borrelia* were detected in 18% of all cases of pCBCL[8]; similar findings have been reported from Scotland[9].

At present, no other microorganism has been convincingly linked to the development of pCBCL. However, it should be noted that pCBCLs have been described in immunosuppressed patients, including those with AIDS and solid organ transplant recipients, and reversible pCBCLs have been observed in patients undergoing therapy with methotrexate (in particular those with rheumatoid arthritis), thus suggesting that immune dysregulation may play a role in the development of this disease[10–12].

CLINICAL FEATURES

In the WHO-EORTC 2018 and ICC 2022 classification schemes, pCBCLs have been divided into five major types (see Table 119.1)[1,3]. Follicle center lymphoma and marginal zone B cell lymphoproliferative disorder are characterized by an indolent clinical behavior, whereas diffuse large B cell lymphoma, leg type, and intravascular diffuse large B cell lymphoma have an aggressive clinical behavior. A further type, Epstein–Barr virus (EBV)-positive mucocutaneous ulcer, is characterized by an indolent behavior. It must be emphasized that, in addition to pCBCLs, the skin can be a site of secondary involvement for practically all types of extracutaneous (usually nodal) B cell lymphomas and leukemias. Complete staging should be performed in all patients with a confirmed diagnosis of high-grade B cell lymphoma involving the skin. This includes a complete blood examination, flow cytometry of peripheral blood, CT examination of the chest, abdomen and pelvis, and, if possible, positron emission tomography (PET)[13]. On the other hand, cutaneous low-grade B cell lymphomas without extracutaneous symptoms are only rarely upstaged by CT of the chest, abdomen and pelvis, functional imaging (PET-CT scan), or bone marrow biopsy[13]. Thus, extensive radiologic imaging and bone marrow biopsy is viewed as superfluous in the staging and follow-up of patients with indolent types of pCBCL confined to the skin[13,14]. A recommended staging evaluation for patients with CBCL is summarized in Table 119.2.

Primary Cutaneous Follicle Center Lymphoma

*P*rimary *c*utaneous *f*ollicle *c*enter *l*ymphoma (PCFCL) is defined as a neoplastic proliferation of germinal center cells confined to the skin. It represents a common subtype of pCBCL.

Clinically, patients present with solitary or grouped, pink- to plum-colored papules, plaques or tumors, which, especially on the trunk, can be surrounded by patches of erythema (Fig. 119.1 & 119.2)[15]. The term *Crosti's lymphoma* has been used to denote those patients with a peripheral patch of erythema. Ulceration is uncommon. Occasionally patients present with miliary and/or agminated small papules that can have an acneiform appearance[16]. Preferential locations are the scalp and forehead or the back. The skin lesions are usually asymptomatic, and, as a rule, B symptoms (i.e. fever, night sweats, weight loss) are rare. The serum level of lactate dehydrogenase (LDH), which is a powerful prognostic factor in systemic lymphomas, is within normal limits.

The prognosis is favorable[1,17]. Recurrences are observed in up to 50% of patients, but dissemination to lymph nodes or internal organs is rare.

RECOMMENDED STAGING INVESTIGATIONS FOR PATIENTS WITH A CONFIRMED DIAGNOSIS OF B CELL LYMPHOMA INVOLVING THE SKIN		
Type of cutaneous lymphoma	**Low-grade (without extracutaneous symptoms)**	**High-grade**
History and physical examination		
• Presence/absence of "B" symptoms, including fever, night sweats, weight loss, malaise	√	√
• Complete lymph node examination	√	√
• Palpation of abdomen for hepatosplenomegaly	√	√
• Examination of oral cavity	√	√
• History of organ transplantation and/or other immune suppression (e.g. HIV, iatrogenic, congenital)	√	√
Laboratory studies		
• Complete blood count with differential and platelet count	√	√
• Comprehensive serum chemistries including LDH	√	√
• Flow cytometry of peripheral blood mononuclear cells	√ (optional)	√
Imaging studies		
• Ultrasound of abdomen and superficial lymph nodes as screening prior to PET-CT or CT scan	√	√
• Whole-body PET-CT scan or CT scan if PET-CT not available	√*	√
Additional studies as clinically indicated		
• Bone marrow biopsy	√*,†	√
• Excisional biopsy of enlarged lymph nodes or other suspicious lesions	√*	√
• PCR analysis for *Borrelia* spp. DNA in patients from endemic areas (Europe) or travelers to endemic areas	√	√

*Only if suspicion for extracutaneous lymphoma.
†In the US, often replaced by flow cytometry plus PET-CT.

Table 119.2 Recommended staging investigations for patients with a confirmed diagnosis of B cell lymphoma involving the skin. CT, computed tomography; HIV, human immunodeficiency virus; LDH, lactate dehydrogenase; PCR, polymerase chain reaction; PET, positron emission tomography.

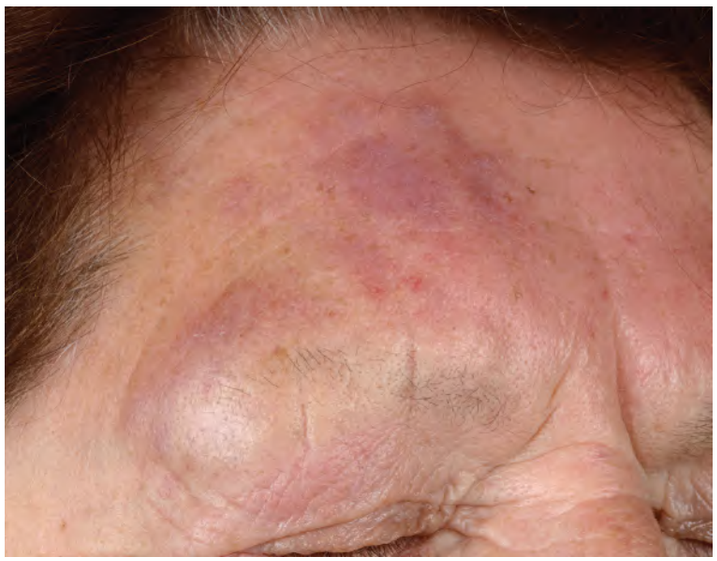

Fig. 119.1 Cutaneous follicle center lymphoma. Prominent pale pink nodule of the lateral eyebrow. The nodule is accompanied by infiltrated darker pink plaques on the forehead.

Downloaded for Anonymous User (n/a) at Egyptian Knowledge Bank from ClinicalKey.com by Elsevier on March 10, 2024. For personal use only. No other uses without permission. Copyright ©2024. Elsevier Inc. All rights reserved.

Fig. 119.2 Cutaneous follicle center lymphoma. Large nodule on the upper back. Note the surrounding erythematous papules, patches, and plaques (Crosti's lymphoma).

Fig. 119.3 Cutaneous marginal zone B cell lymphoproliferative disorder. Well-circumscribed, erythematous nodule on the back that was firm to palpation (inset).

Primary Cutaneous Marginal Zone B Cell Lymphoproliferative Disorder

*P*rimary *c*utaneous *m*arginal *z*one B cell *l*ymphoproliferative *d*isorder (PCMZLD) has been recognized as a distinct variant of low-grade malignant pCBCL[5,18]. In the ICC classification of 2022 it is no longer grouped with other marginal zone lymphomas of mucosa-associated lymphoid tissue, and it has been downgraded to a lymphoproliferative disorder rather than a true lymphoma[3]. It is still listed as a lymphoma in the 5th edition of the WHO classification[18a]. Of note, cases classified in the past as *primary cutaneous immunocytoma* or *primary cutaneous plasmacytoma* represent examples of PCMZLD with prominent lymphoplasmacytic or plasmacytic differentiation, respectively, and the terms cutaneous immunocytoma and cutaneous plasmacytoma are not used in the WHO-EORTC and ICC 2022 classification schemes[1–3].

Clinically, patients present with recurrent pink–violet to red–brown papules, plaques, and nodules that favor the extremities (upper > lower) or trunk (Fig. 119.3 & 119.4). Generalized lesions can be observed in a small number of patients. Ulceration rarely occurs and skin lesions are usually asymptomatic. As a rule, B symptoms (i.e. fever, night sweats, weight loss) are not present. The serum level of LDH is within normal limits. In some instances, resolution of lesions may be accompanied by secondary anetoderma due to loss of elastic fibers in the area of the tumor infiltrate.

The prognosis of PCMZLD is excellent. In a study of 32 patients with PCMZLD, none of them developed lymph node or internal involvement during a mean follow-up of more than 4 years[5].

Of note, PCMZLD can arise in areas affected by acrodermatitis chronica atrophicans and it may be linked to infection by *Borrelia* spp. more frequently than are other types of pCBCL, particularly in Europe[8].

Fig. 119.4 Cutaneous marginal zone B cell lymphoproliferative disorder. Two thick pink–violet plaques on the foot, one of which has a flat surface. Molecular analysis revealed *Borrelia* DNA within the infiltrate. In the past, these tumors, which demonstrated prominent lymphoplasmacytic differentiation histologically, were classified as cutaneous immunocytomas.

Primary Cutaneous Diffuse Large B Cell Lymphoma, Leg Type

Primary cutaneous *d*iffuse *l*arge *B c*ell *l*ymphoma, *l*eg *t*ype (DLBCLLT), represents a form of pCBCL that is characterized by a predominance of large round cells (centroblasts, immunoblasts) positive for Bcl-2, MUM-1 (*mu*ltiple *m*yeloma oncogene *1* or interferon regulatory factor 4 [expressed by post germinal center B cells and plasma cells]), and FOX-P1[1]. It occurs almost exclusively in elderly patients, predominantly women.

Clinically, patients present with solitary or clustered, erythematous to red–brown nodules, located primarily on the distal aspect of one leg (Fig. 119.5). In some patients, lesions may arise on both lower extremities contemporaneously or within a short interval of time. Ulceration may also occur. Small erythematous papules can be seen adjacent to larger nodules. It must be emphasized that in ~20% of patients, tumors with similar morphologic and phenotypic features can arise in areas other than the lower extremities, but the designation DLBCLLT is still applied[19].

The prognosis of DLBCLLT is less favorable than that of other types of pCBCL, with an estimated disease-specific 5-year survival rate of 50%–60%[1].

It must be stressed that some patients with *nodal* large B cell lymphoma can present with secondary cutaneous lesions located exclusively on the legs, underlying the need for complete staging investigations before a diagnosis of DLBCLLT can be established. PET scans are superior to CT studies for discovering evidence of systemic disease.

Intravascular Diffuse Large B Cell Lymphoma

*I*ntra*v*ascular *d*iffuse *l*arge *B c*ell *l*ymphoma (IVDLBCL) is a rare malignant proliferation of large B lymphocytes within blood vessels[4]. Most patients have a B cell phenotype, but a T cell variant has been reported. In occasional patients, the skin may be the only affected site, although more often there is systemic involvement (including the CNS) from the onset. Clinically, patients present with indurated, erythematous or violaceous patches and plaques, preferentially located on the trunk and thighs and often with prominent telangiectasias. The clinical appearance is not typical of cutaneous lymphoma, and it may sometimes suggest a diagnosis of panniculitis or vascular tumors. Interestingly, in several patients, IVDLBCL was observed to be confined to cherry angioma lesions. The prognosis of IVDLBCL is poor, and the disease usually runs an aggressive course[20].

Downloaded for Anonymous User (n/a) at Egyptian Knowledge Bank from ClinicalKey.com by Elsevier on March 10, 2024. For personal use only. No other uses without permission. Copyright ©2024. Elsevier Inc. All rights reserved.

Fig. 119.5 Cutaneous diffuse large B cell lymphoma, leg type. On both lower legs, multiple violet–brown nodules as well as a large flat tumor.

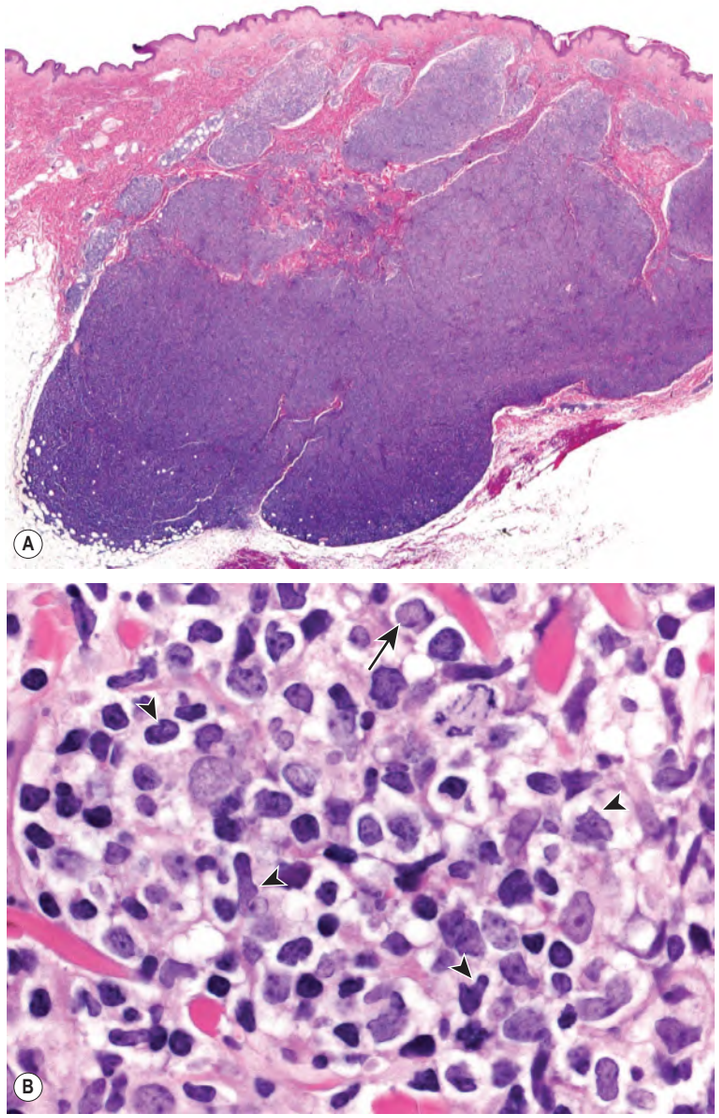

Fig. 119.6 Cutaneous follicle center lymphoma, diffuse type. A Diffuse infiltrate *without* a follicular pattern. **B** Centroblasts (arrow) and medium- and large-sized centrocytes (cleaved cells; arrowheads) predominate.

Precursor B Lymphoblastic Lymphoma/Leukemia

B cell lymphoblastic lymphomas/leukemias are malignant proliferations of precursor B lymphocytes. Reports of patients whose primary site is the skin have been rare. It should be emphasized, however, that all patients should be assumed to have, and treated for, systemic disease, even in the absence of documented systemic involvement at the time of presentation.

In contrast to the other cutaneous B cell lymphomas, this disease shows a clear-cut predilection for children and young adults[21]. Clinically, patients present with solitary large erythematous tumors, commonly located on the head and neck. Patients with primary skin disease often have asymptomatic lesions of a few weeks' duration. Those with secondary skin lesions may have systemic symptoms, e.g. weight loss, fever, fatigue, night sweats. The serum level of LDH is often elevated, reflecting the aggressive, and often systemic, nature of the disease. The disease is highly aggressive, and the prognosis of untreated patients is poor.

Other Cutaneous B Cell Lymphomas

Rare cases of pCBCL do not fit within the subtypes reviewed above. In the ICC 2022 classification, these patients are divided amongst several categories, including (but not limited to) large B cell lymphomas arising in the setting of immune suppression, plasmablastic lymphoma, and diffuse large B cell lymphoma, not otherwise specified (NOS)[2,3]. Plasmablastic lymphoma is a rare lymphoma that usually arises within the oral cavity in patients with severe immunosuppression, especially HIV-related[4], but can also be observed in immunocompetent patients. It is often associated with infection by EBV.

EBV-positive mucocutaneous ulcer is a low-grade B cell malignancy that usually arises within the context of immune senescence or in immunocompromised hosts. It most commonly presents as ulcers of the oral mucosa.

PATHOLOGY

In addition to routine histology and immunohistochemical phenotyping, which when combined are sufficient for the diagnosis of most cases of pCBCL, molecular investigations are becoming increasingly important for precise stratification of patients with aggressive B cell lymphomas.

Primary Cutaneous Follicle Center Lymphoma

In PCFCL, nodular or diffuse infiltrates are seen within the entire dermis, often extending into the subcutaneous fat (Fig. 119.6A)[4]. The epidermis is usually spared. A clear-cut follicular pattern with formation of neoplastic germinal centers was observed in only a minority of cases (25%) in the series from Graz (Fig. 119.7)[17]. However, a higher percentage of cases may show at least some follicular architecture. In those with a follicular pattern, the neoplastic follicles show morphologic features of malignancy, including the presence of a reduced or absent mantle zone, the lack of tingible body macrophages, and a monomorphism of the follicles – so-called "dark" and "clear" areas are no longer recognizable (see Fig. 119.7 [inset])[17].

In both the follicular and diffuse variants, centrocytes (small to large, cleaved follicle center cells) predominate within the neoplastic infiltrate (Fig. 119.6B) and are admixed with a variable number of centroblasts (large, non-cleaved follicle center cells with prominent nucleoli), immunoblasts, small lymphocytes, histiocytes, and, in some cases, eosinophils and plasma cells. In contrast to nodal FCLs, grading is not used for the classification of PCFCL. On a cytomorphologic basis, some cases of PCFCL with a diffuse pattern of growth and a predominance of large centrocytes have the appearance of a large cell lymphoma, but the prognosis of these cases is similar to that of lesions without the large cell morphology[1,19]. Patients with a monotonous proliferation of centroblasts and/or immunoblasts should be classified as having diffuse large B cell lymphoma. An accompanying infiltrate of small T lymphocytes and histiocytes/macrophages is usually present, and, in some instances, these cells can be predominant. In rare cases, a population of monoclonal

Downloaded for Anonymous User (n/a) at Egyptian Knowledge Bank from ClinicalKey.com by Elsevier on March 10, 2024. For personal use only. No other uses without permission. Copyright ©2024. Elsevier Inc. All rights reserved.

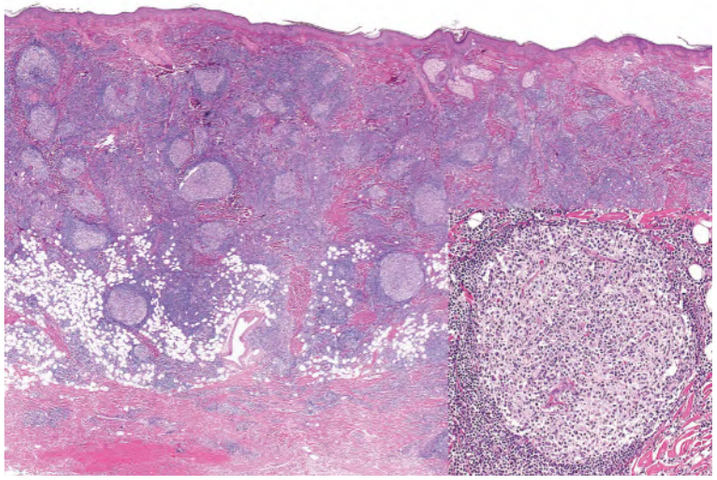

Fig. 119.7 Cutaneous follicle center lymphoma, follicular type. Neoplastic follicles with a monomorphous morphology (lack of polarization) within the entire dermis and superficial subcutis. Note the absence of dark and clear areas within the central portion of the follicle (inset).

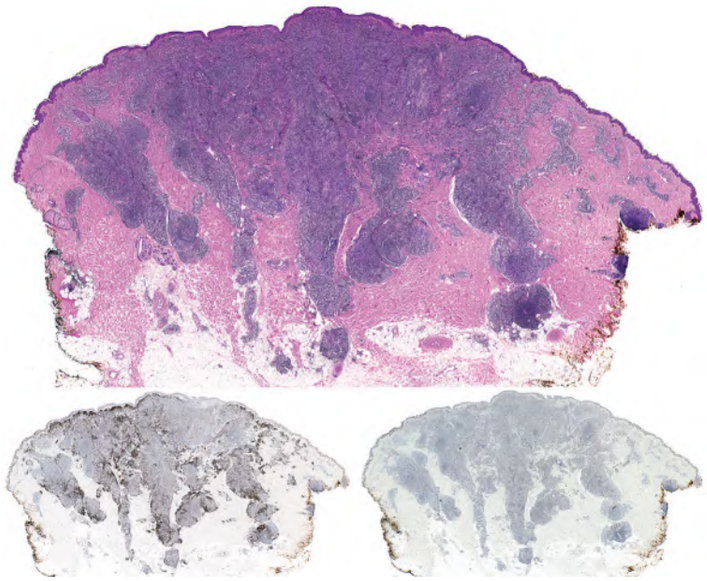

Fig. 119.8 Cutaneous marginal zone B cell lymphoproliferative disorder. Nodular lymphoid infiltrate within the entire dermis. Monotypic expression of kappa immunoglobulin light chain (left inset) with negativity for lambda light chain (right inset).

plasma cells belonging to the neoplastic clone can be observed, representing a pitfall in the differential diagnosis with PCMZLD[21a,21b].

In addition to cases characterized by numerous large cells, morphologic variants of PCFCL include those with a predominant spindle cell morphology, which can simulate sarcomas or other spindle cell tumors histopathologically, thus representing a diagnostic pitfall[22]. Lesions in which a few B cell blasts are admixed with numerous T lymphocytes have been classified as "T cell/histiocyte-rich B cell lymphomas", and in the skin probably represent another rare morphologic variant of PCFCL[4]. Of note, when there is nodal involvement with this latter morphologic variant, it is classified as a large B cell lymphoma.

The tumor cells express B cell-associated antigens (CD20, CD79a, PAX-5); they are $CD5^-$ and $CD43^-$ (see Table 0.13 for the specificities of CD markers). When follicles are present, they are characterized by an irregular network of $CD21^+$ follicular dendritic cells. Bcl-6 (a marker of germinal center cells and other lymphoid cells) is positive in virtually all cases, irrespective of the pattern of growth. In most cases with a follicular growth pattern, and in a minority of those with a diffuse growth pattern, neoplastic cells also stain positively for CD10. The presence of small clusters of Bcl-6^+ cells outside the follicles is considered strongly suggestive of a diagnosis of PCFCL[16]. Of note, Bcl-6 is also expressed by a subset of T lymphocytes (follicular T helper lymphocytes), but these cells are never arranged within clusters in cases of PCFCL.

In the vast majority of cases, staining for the protein product of *BCL-2* (Bcl-2) yields negative results within neoplastic follicles, representing a major difference from follicular lymphomas arising within lymph nodes[23]. Positivity for Bcl-2 by >75% neoplastic lymphocytes has been related to a higher rate of cutaneous recurrence[23a]. A useful, though somewhat counterintuitive, distinguishing immunohistochemical feature is the *lower* degree of proliferative activity within *malignant* follicles as detected by the anti-Ki-67 antibody (expressed by proliferating cells), in contrast to the *strong* Ki-67-positivity in *reactive* follicles[17]. In cases with large cell morphology (predominance of large cleaved cells), immunohistochemical staining for MUM-1 is either negative or is positive in a minority of neoplastic cells (in contrast to strong expression of MUM-1 by DLBCLLT; see below)[1,19]. The interchromosomal 14;18 translocation, typically found in *nodal* follicular lymphomas, is present in a minority of PCFCLs[23]. Therefore, the presence of the 14;18 translocation and/or expression of Bcl-2 should raise suspicion that the patient has a systemic lymphoma involving the skin. Analysis of the genes that encode the joining segment (J_H) and other regions of the immunoglobulin heavy chain (IGH) reveals the presence of a monoclonal rearrangement in the majority of patients (60%–70%). When gene expression in PCFCLs was analyzed via cDNA microarrays, a *germinal center cell signature pattern* was observed.

Analysis of morphologic, immunohistochemical, and molecular data suggests that follicular lymphomas originating in the lymph nodes and the skin, although characterized by a similar morphologic pattern, have different pathogenic mechanisms.

Primary Cutaneous Marginal Zone B Cell Lymphoproliferative Disorder

Histology of PCMZLD shows a patchy, nodular, or diffuse infiltrate involving the dermis and subcutaneous fat. The epidermis is spared. A characteristic pattern can be observed at scanning magnification (Fig. 119.8): nodular infiltrates (sometimes containing reactive germinal centers) are surrounded by a pale-staining population of small- to medium-sized cells with indented nuclei, inconspicuous nucleoli, and abundant pale cytoplasm – variously described as marginal zone cells, centrocyte-like cells, or monocytoid B cells (Fig. 119.9A)[4,5]. In addition, plasma cells (at the margins of the infiltrate), lymphoplasmacytoid cells, small lymphocytes, and occasional large blasts are observed. Eosinophils are also a common finding. In some patients, there may be a granulomatous reaction with epithelioid and giant cells. Cases with a predominance of lymphoplasmacytoid lymphocytes were once classified as cutaneous immunocytomas, but are now considered variants of PCMZLD. PAS-positive intranuclear inclusions (Dutcher bodies) are sometimes observed and represent a valuable clue to the diagnosis (Fig. 119.9B). Occasionally, the predominant cell type is a plasma cell (Fig. 119.9C), and although such cases used to be classified as primary cutaneous plasmacytomas, they are now also considered to be variants of PCMZLD[1]. Finally, rare cases are characterized by the predominance of large blastoid cells resembling plasmablasts (Fig. 119.9D)[24]. Solitary cutaneous nodular amyloidosis (cutaneous amyloidoma) harboring a small monoclonal population of plasma cells may represent a peculiar, rare variant of PCMZLD[25].

The centrocyte-like cells stain positively for CD20, CD79a, Fc receptor-like 4 (FCRL4/IRTA1)[26], and Bcl-2; they are negative for CD5, CD10, and Bcl-6. In the overwhelming majority of cases, intracytoplasmic monotypic expression of immunoglobulin light chains (either κ or λ, but not both) can be observed (see Fig. 119.8; Fig. 119.10). The monoclonal population of B lymphocytes is often characteristically arranged at the periphery of the cellular aggregates. Staining for proliferation markers also shows increased positivity at the periphery of the nodules (as well as in reactive germinal centers). IgG4 expression is observed in less than half of cases with plasmacytic differentiation but is not associated with systemic IgG4-related disease[27]. Monoclonal rearrangement of *IGH* can be detected in the majority of cases (60%–80%).

PCMZLDs express class-switched immunoglobulins, e.g. the same clone can switch from IgM to IgG or IgA[28]. Although the B lymphocyte changes antibody production from one class to another, the cell retains affinity for the same antigen. PCMZLD are also characterized

Downloaded for Anonymous User (n/a) at Egyptian Knowledge Bank from ClinicalKey.com by Elsevier on March 10, 2024. For personal use only. No other uses without permission. Copyright ©2024. Elsevier Inc. All rights reserved.

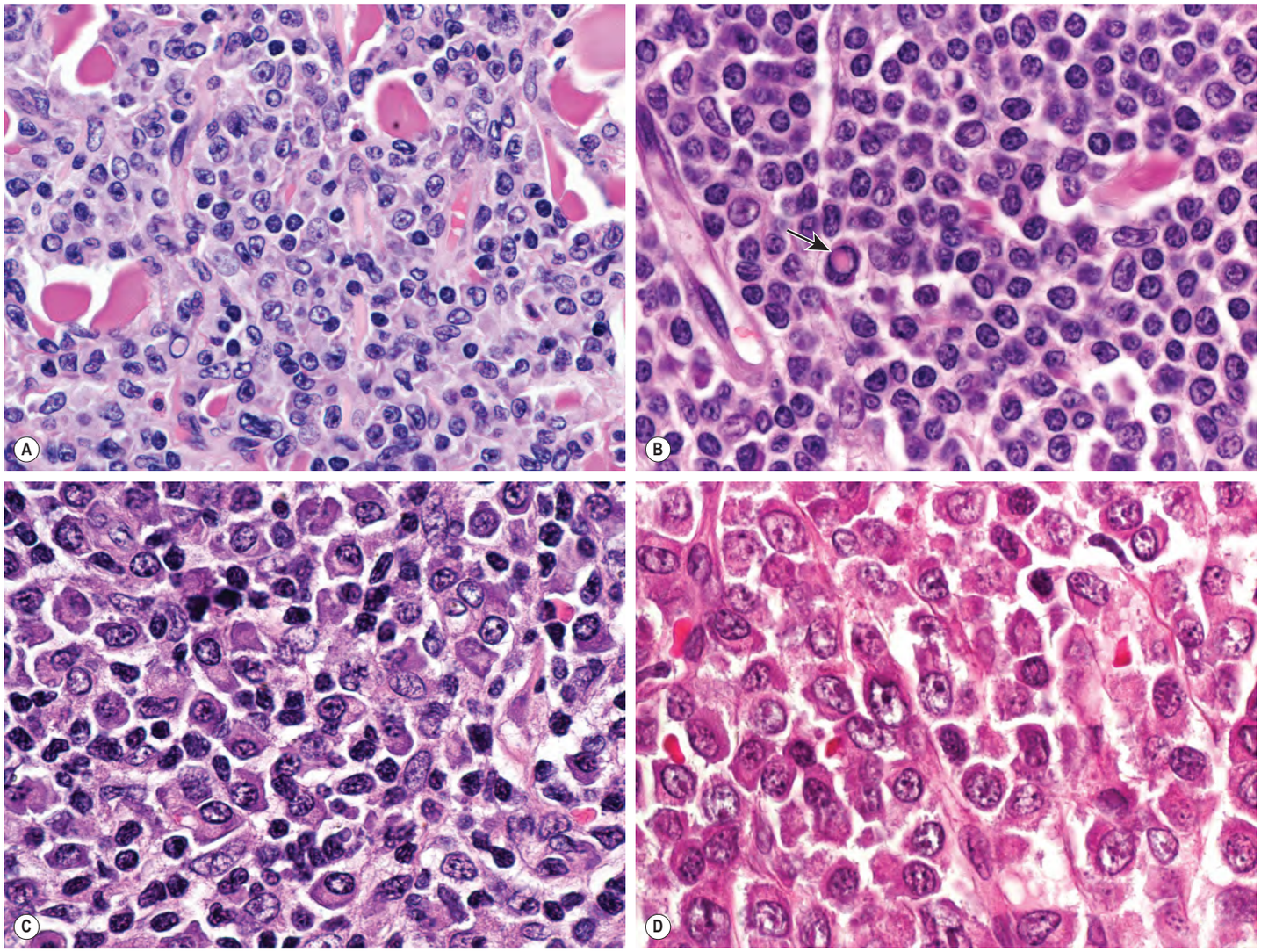

Fig. 119.9 Cutaneous marginal zone B cell lymphoproliferative disorder – spectrum of cell types. A Admixture of marginal zone cells, plasmacytoid cells, and plasma cells. **B** Predominance of lymphoplasmacytoid cells (formerly classified as cutaneous immunocytoma; note an intranuclear eosinophilic inclusion [Dutcher body, arrow]). **C** Predominance of plasma cells (formerly classified as cutaneous plasmacytoma). **D** Predominance of large blastoid cells similar to plasmablasts.

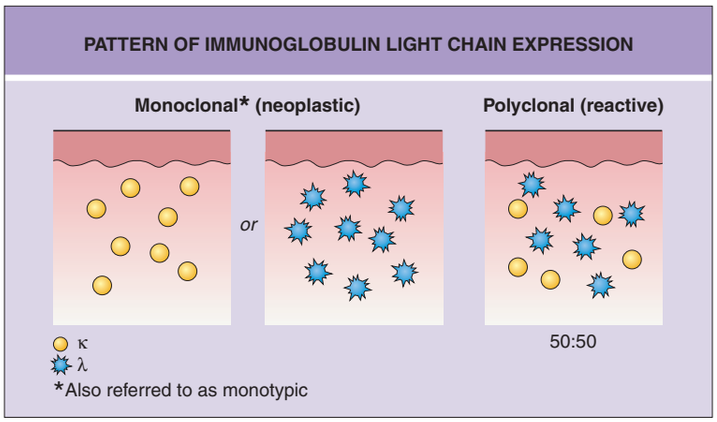

Fig. 119.10 Pattern of immunoglobulin light chain expression. Detection of monoclonal expression of immunoglobulin light chains (κ or λ) is a key diagnostic feature for primary cutaneous marginal zone B cell lymphoproliferative disorder. Monoclonality is defined as a >10/1 ratio.

by aberrant somatic hypermutations allowing binding to different antigens[29]. A minority of PCMZLD express IgM (non-switched cases), but this is associated with a higher frequency of extracutaneous dissemination.

A particular translocation, t(14;18)(q32;21), that involves *IGH* and *MALT1* has been detected in a subset of PCMZLD (~30%) as well as MALT lymphomas arising in organs other than the skin. In gene expression studies utilizing cDNA microarrays, PCMZLDs had a *plasma cell signature pattern*. Other genetic aberrations include trisomy 3 (with upregulation of *FOXP1*) and rarely an 11;18 or a 3;14 translocation[30]. However, in more than 50% of patients, no molecular abnormalities have been found.

Primary Cutaneous Diffuse Large B Cell Lymphoma, Leg Type

In DLBCLLT, a dense diffuse infiltrate is seen within the dermis and subcutis. The infiltrate usually involves the entire papillary dermis extending to the dermal–epidermal junction. Involvement of the epidermis by clusters of large atypical cells, simulating the Pautrier microabscesses found in cutaneous T cell lymphoma, can be observed in some cases (B cell epidermotropism), representing a potential diagnostic pitfall[4]. The neoplastic infiltrate consists predominantly of immunoblasts (large round cells with abundant cytoplasm and prominent nucleoli) and centroblasts (Fig. 119.11). Of note, cases of pCBCLs with a predominance of large cleaved cells (i.e. large centrocytes) are classified among the PCFCLs (see above)[1]. Reactive small lymphocytes are usually few in number, and mitoses are frequent. The common finding of immunoglobulin gene hypermutations is evidence that DLBCLLT is a large cell lymphoma, representing post germinal center lymphocytes that originated from lymphocytes of the germinal center.

Downloaded for Anonymous User (n/a) at Egyptian Knowledge Bank from ClinicalKey.com by Elsevier on March 10, 2024. For personal use only. No other uses without permission. Copyright ©2024. Elsevier Inc. All rights reserved.

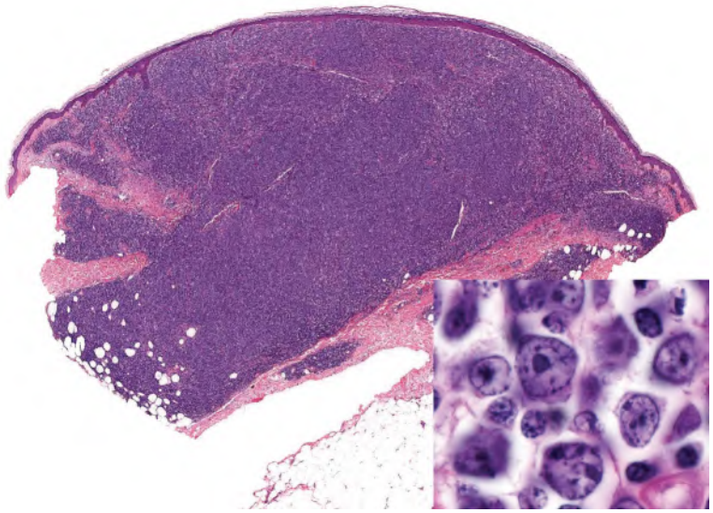

Fig. 119.11 Cutaneous diffuse large B cell lymphoma, leg type. Within the entire dermis, there is a dense, diffuse lymphoid infiltrate. Large cells with a round morphology (mainly immunoblasts) predominate (inset).

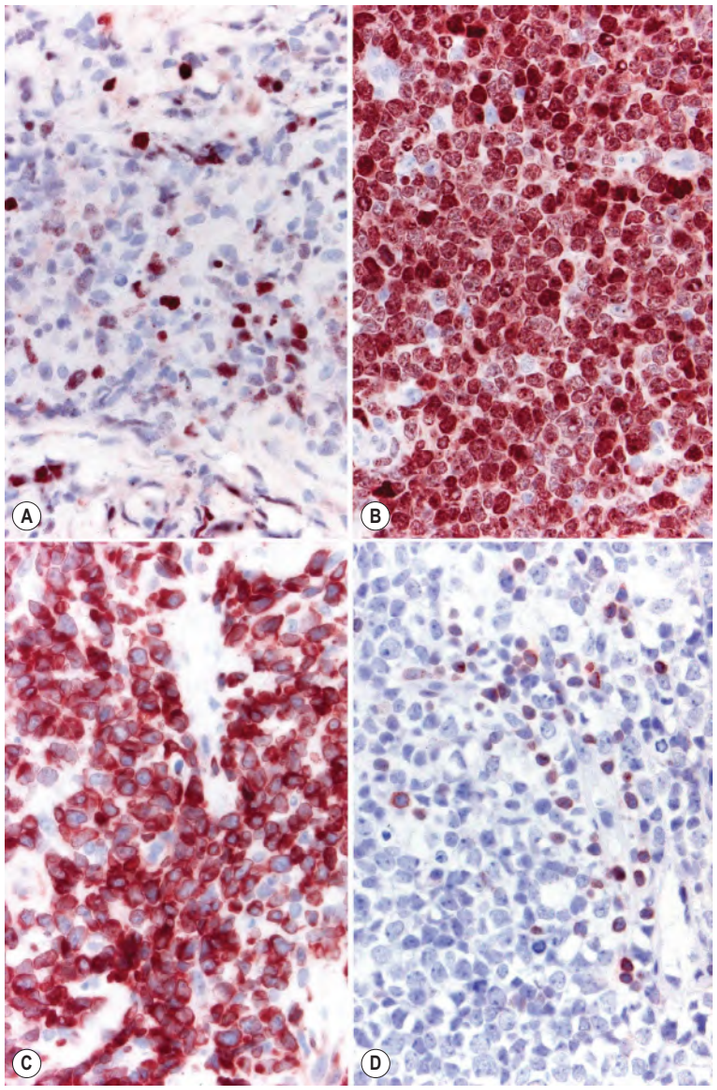

Fig. 119.12 Immunohistochemical staining with anti-Bcl-2 and anti-MUM-1 antibodies. Staining with anti-Bcl-2 antibody shows negativity (except for reactive small lymphocytes) in follicle center lymphoma, diffuse type (**A**) and positivity of most tumor cells in diffuse large B cell lymphoma, leg type (**B**). Anti-MUM-1 antibody stains virtually all the tumor cells in primary cutaneous diffuse large B cell lymphoma, leg type (**C**) while only a minority of cells are positive in primary cutaneous follicle center lymphoma, diffuse type (**D**).

Neoplastic cells are positive for B cell markers (CD20, CD79a, PAX-5, IgM), but there can be (partial) loss of antigen expression. Bcl-2, MUM-1 (see above), FOX-P1, and MYC are expressed by neoplastic cells in most patients[1,19,31]. These markers are useful in the differential diagnosis of DLBCLLT from PCFCL, diffuse type; in the latter, Bcl-2, MUM-1, and FOX-P1 are usually either negative or expressed by a small minority of cells (Fig. 119.12). The tumors demonstrate monoclonal rearrangement of *IGH*. The interchromosomal 14;18 translocation is not present. An algorithmic approach to the diagnosis of cutaneous diffuse large B cell lymphomas is provided in Fig. 119.13. The differential expression of lymphoid markers in various types of diffuse large B cell lymphoma with cutaneous involvement is summarized in Table 119.3.

Rare cases of otherwise typical cutaneous DLBCLLT show expression of CD30 by neoplastic cells[19]. In nodal diffuse large B cell lymphomas, CD30 expression was associated with a better prognosis, but data on DLBCLLT are lacking. Hypermethylation of the genes that encode p15 and/or p16 (*CDKN2B*, *CDKN2A*), resulting in decreased expression of these proteins, has been observed in some patients. 9p21 deletions, possibly leading to loss-of-function of *CDKN2A*, are associated with a worse prognosis. A worse prognosis has also been noted in patients whose tumors have *MYD88* mutations.

In *nodal* diffuse large B cell lymphomas that have a rearrangement of *MYC* associated with additional rearrangements in *BCL-2* and/or *BCL-6* ("double-hit" or "triple-hit" lymphomas) have a worse prognosis. A poor prognosis is also associated with expression of the respective proteins as detected by immunohistochemistry ("double expression" or "triple expression" patterns). Data regarding primary cutaneous B cell lymphomas are still fragmentary, but it appears that *MYC* rearrangements are more common than in B cell lymphomas at extracutaneous sites, whereas double-hits are very rare and do not affect prognosis[32,33]. Expression of MYC, Bcl-2 and Bcl-6 is common in primary cutaneous lymphomas, but the prognostic value of "double expression", if any, is still unclear[32,33]. While the cut-off values for determining positivity of Bcl-2 and MYC expression within cells lack uniformity, currently accepted cut-off points are 50% for Bcl-2 and 40% for MYC.

Genetic data obtained by FISH or microarray chip technologies have confirmed that DLBCLLTs show clear molecular differences from PCFCL, diffuse type, confirming the need of classifying these cases separately[34]. The molecular profile of DLBCLLT is similar to that observed in diffuse large B cell lymphomas of the lymph nodes, with the *signature pattern of an activated B lymphocyte*[35].

Intravascular Diffuse Large B Cell Lymphoma

IVDLBCL is characterized by a proliferation of large atypical lymphocytes that fills dilated blood vessels within the dermis and subcutaneous tissues (Fig. 119.14). The malignant cells are large with scanty cytoplasm and often have prominent nucleoli. They are positive for B cell-associated markers as well as for Bcl-2, MUM-1, and FOX-P1. Staining with endothelial cell-related antibodies (e.g. CD31, CD34) highlights the characteristic intravascular location of the cells. Molecular analysis shows monoclonal rearrangement of *IGH*. The genetic profile is similar to that observed in diffuse large B cell lymphomas – activated B cell type.

Precursor B Lymphoblastic Lymphoma/Leukemia

Histologically, precursor B lymphoblastic lymphoma/leukemia shows a monomorphous proliferation of medium-sized cells with scanty cytoplasm and round or convoluted nuclei with fine chromatin (Fig. 119.15). A "starry sky" pattern is commonly seen at low power, due to the presence of macrophages with inclusion bodies ("tingible bodies"). Another characteristic feature is the arrangement of neoplastic cells in a "mosaic-stone" pattern. Mitoses and necrotic cells are abundant. It must be stressed that histologic features alone do not allow differentiation of lymphoblastic lymphomas of B cell phenotype from those of T cell lineage. Immunohistology demonstrates positive staining for TdT (terminal deoxynucleotidyl transferase; present on precursor

Downloaded for Anonymous User (n/a) at Egyptian Knowledge Bank from ClinicalKey.com by Elsevier on March 10, 2024. For personal use only. No other uses without permission. Copyright ©2024. Elsevier Inc. All rights reserved.

T and B cells), PAX-5, CD10, and the cytoplasmic μ-chain of immunoglobulins, and in most cases, CD20 and CD79a. CD20 is negative in the pre-pre-B cell variant, which is CD34$^+$. Molecular analyses usually show a monoclonal rearrangement of *IGH* and a polyclonal pattern for T cell receptor genes (*TCR*), but a lack of rearrangement of *IGH* or monoclonal rearrangement of both *TCR* and *IGH* may be observed.

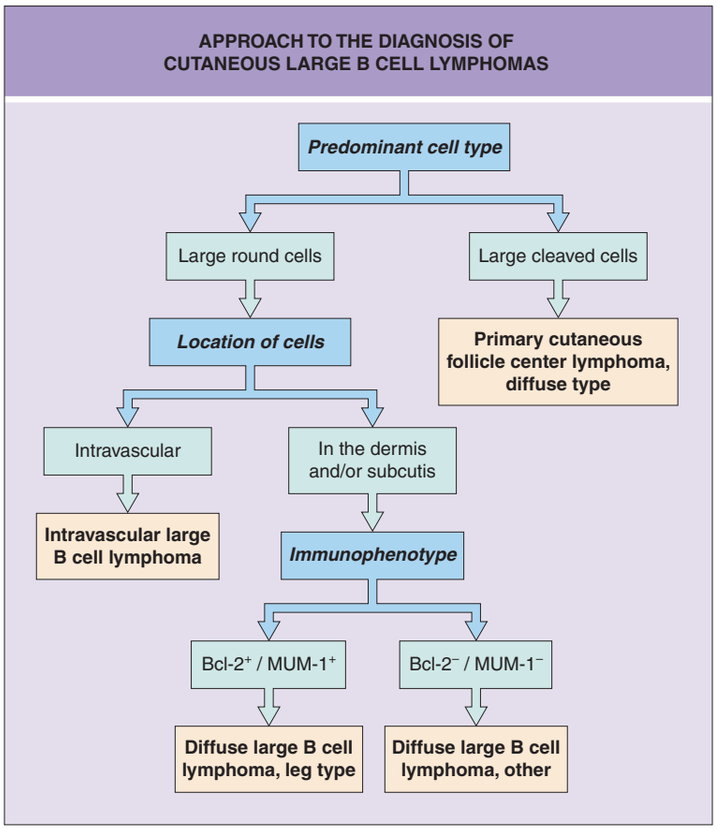

Fig. 119.13 Approach to the diagnosis of cutaneous large B cell lymphomas. In most patients with primary cutaneous diffuse large B cell lymphoma, leg type, the neoplastic cells strongly express MUM-1 and FOX-P1 (as well as Bcl-2), whereas in primary cutaneous follicle center lymphoma, diffuse type, these stains are usually either negative or expressed by a small minority of cells (see Fig. 119.12).

Other Cutaneous B Cell Lymphomas

EBV$^+$ mucocutaneous ulcer is characterized by the presence of atypical cells positive for CD30 and PAX5 within a polymorphous background, mimicking the features observed in Hodgkin lymphoma. EBV is detected within the atypical cells, but positivity is also observed in small lymphocytes, representing a clue for differentiation from true Hodgkin lymphoma (where EBV-positivity is limited to large, atypical cells)[36]. In addition, clinical features of the two entities are completely different.

Plasmablastic lymphoma is characterized by a proliferation of plasmablasts with large eccentric nuclei, abundant cytoplasm, and prominent nucleoli. While the tumor cells may appear lymphoid, they stain like plasma cells. They are positive for CD38, CD138 and MUM-1, but negative for CD20; they express monotypic immunoglobulin light chains. *In situ* hybridization for EBV (EBER-1) is positive in the vast majority of cases.

DIFFERENTIAL DIAGNOSIS

Although differential diagnoses of pCBCLs vary according to the type of lymphoma, in general they include inflammatory processes that may simulate malignant lymphomas clinically and/or histopathologically, referred to as cutaneous lymphoid hyperplasia, lymphocytoma cutis or "pseudolymphoma" (see Ch. 121). It must be emphasized that a definitive diagnosis of pCBCL can be reached only after careful examination of the clinical, histopathologic, immunophenotypic and molecular features; in some cases, only repeated examination of the patient and sequential biopsy specimens will allow the correct classification[4]. A schematic diagram with examples of the use of immunohistochemical stains and PCR in the differential diagnosis of pCBCLs is presented in Figure 119.16.

Patients for whom no definitive diagnosis can be established at the time of presentation should provisionally be classified as having "cutaneous atypical lymphoid proliferation of B cell lineage", and they should be re-examined at regular intervals[4]. A complete staging investigation does not belong in the diagnostic evaluation of these patients; that is, patients without a definitive diagnosis of CBCL should not be screened for extracutaneous disease until the diagnosis is established with certainty[4]. In contrast, once the diagnosis of CBCL has been established, complete staging is mandatory, as clinicopathologic features alone do not allow for the differentiation of primary from secondary cutaneous B cell lymphomas (see Table 119.2). A diagnostic algorithm for evaluation of patients at first presentation is provided in Figure 119.17.

In the following section, the major differential diagnoses of each of the main types of pCBCL are outlined separately, as they differ according to the lymphoma type.

IMMUNOHISTOCHEMICAL MARKER EXPRESSION IN PRIMARY AND SECONDARY CUTANEOUS LARGE B CELL LYMPHOMAS WITH OVERLAP IN ROUTINE HISTOPATHOLOGIC FINDINGS

	Immunohistochemical marker expression							
	Bcl-2	Bcl-6	CD10	CD5	MUM-1	Cyclin D1	TdT	EBER-1
Primary cutaneous lymphomas								
Follicle center lymphoma, diffuse	–	+	+/–	–	–	–	–	–
Marginal zone lymphoma, blastoid	+	–	–	–	–	–	–	–
Diffuse large B cell lymphoma, leg type	+	+/–	–	–	+	–	–	–
Systemic lymphomas with secondary skin involvement								
EBV$^+$ DLBCL	+/–	–/+	–/+	–	+	–	–	+
Nodal DLBCL	+	+/–	+/–	–/+	+/–	–	–	–
Mantle cell lymphoma, blastic	+	–/+	–	+	–/+	+	–	–
CLL/SLL → Richter syndrome	+/–	–	–	+	–	–	–	–
Burkitt lymphoma	–	+	+	–	–	–	–	+
B lymphoblastic lymphoma	+	–	+	–	–	–	+	–

+/–, majority of cases positive; –/+, majority of cases negative.

Table 119.3 Immunohistochemical marker expression in primary and secondary cutaneous large B cell lymphomas with overlap in routine histopathologic findings. As to be expected, there can be phenotypic overlap amongst these entities. All stain positively for CD20. The most helpful stains are shaded. CLL/SLL, B cell chronic lymphocytic leukemia/small lymphocytic lymphoma; DLBCL, diffuse large B cell lymphoma; EBV, Epstein–Barr virus.

Downloaded for Anonymous User (n/a) at Egyptian Knowledge Bank from ClinicalKey.com by Elsevier on March 10, 2024. For personal use only. No other uses without permission. Copyright ©2024. Elsevier Inc. All rights reserved.

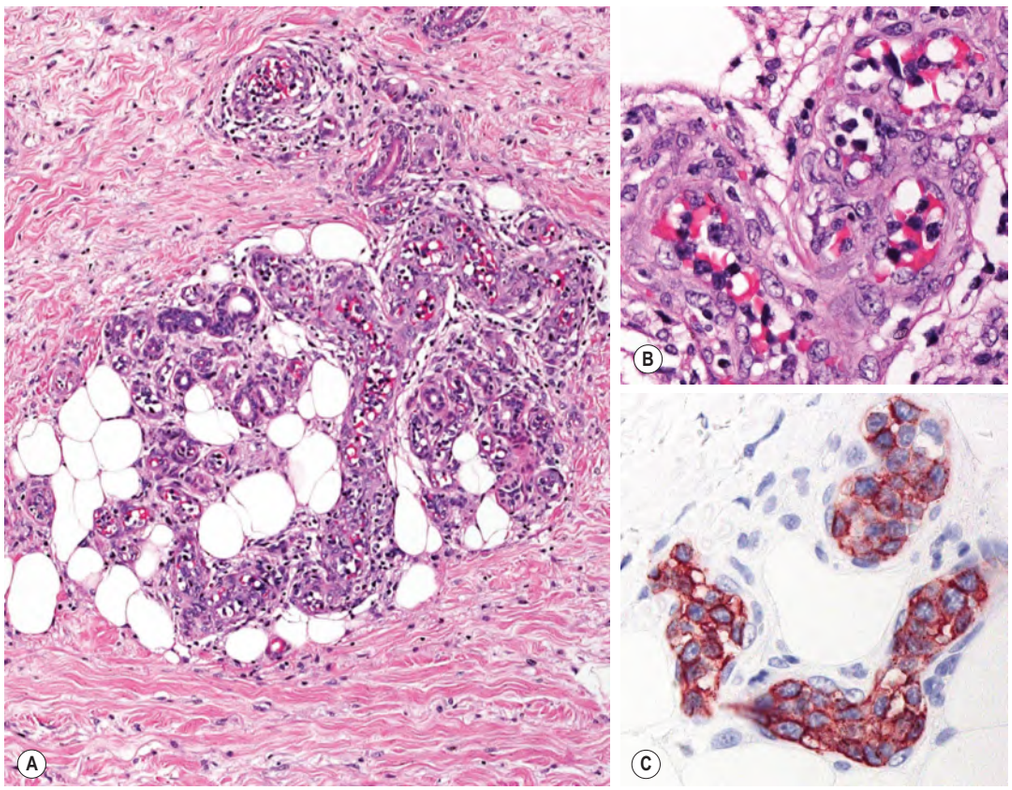

Fig. 119.14 Cutaneous diffuse intravascular large B cell lymphoma – histopathologic features. A Dermal cluster of several small blood vessels filled with large, atypical lymphocytes (**B**) which are positive for CD20 (**C**).

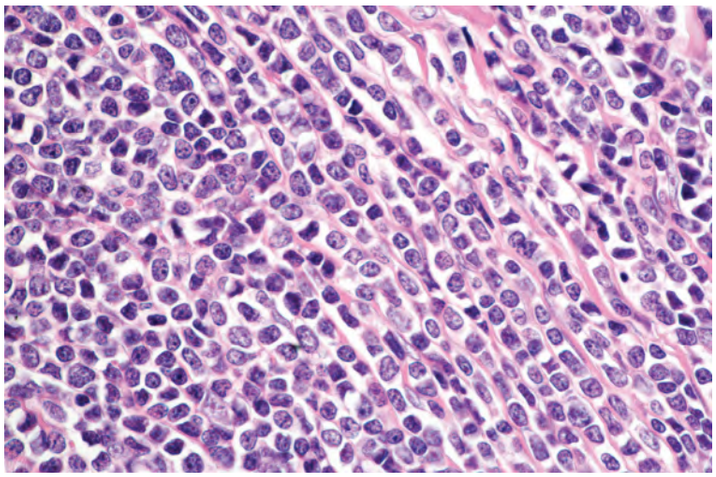

Fig. 119.15 Precursor B lymphoblastic lymphoma/leukemia. Medium-sized blasts with the characteristic "mosaic-stone" linear arrangement.

PCFCL with a follicular pattern of growth should be differentiated from B cell pseudolymphomas with prominent germinal centers, such as *Borrelia*-induced lymphocytoma cutis (cutaneous lymphoid hyperplasia)[17,37]. Lymphocytoma cutis can be triggered by a number of stimuli, including arthropod bites, vaccinations, tattoos and drugs, and it has a predilection for particular body sites such as the earlobes, nipples, and scrotum[37]. Clinically, lesions are usually solitary and relatively small. Although histologically a follicular pattern is almost always observed, germinal centers in lymphocytoma cutis are reactive, and they are accompanied by inflammatory infiltrates with small lymphocytes, plasma cells, and often eosinophils[4,37]. The germinal centers in *Borrelia*-induced lymphocytoma cutis are often devoid of a clear-cut mantle, but they are characterized by the presence of many tingible body macrophages, "clear" and "dark" areas, and a normal (high) proliferation rate[37].

Rare cases of cutaneous PCMZLD can have a prominent presence of reactive germinal centers, and they should be differentiated from the follicular type of PCFCL. In these cases, so-called follicular colonization by neoplastic marginal zone cells can indeed cause significant problems in histopathologic differential diagnosis, similar to what happens in B cell lymphomas of the MALT type. However, the overall architecture of the infiltrate, the presence of a population of monoclonal plasma cells belonging to the neoplastic clone, and the negativity of neoplastic cells for CD10 and Bcl-6 usually allow the diagnosis of cutaneous PCMZLD to be established.

As mentioned previously, secondary cutaneous involvement by primary extracutaneous follicular lymphomas has morphologic and phenotypic features similar or identical to those observed in primary cutaneous B cell lymphoma, except for the usual positivity of neoplastic cells for Bcl-2 in secondary cutaneous lesions. Consequently, the occurrence of a cutaneous follicular lymphoma with clear-cut positivity for Bcl-2 within neoplastic follicles should be considered as a hint (although exceptions can be encountered) for the diagnosis of secondary skin lesions of nodal lymphoma.

The differential diagnosis of **PCMZLD** consists primarily of reactive processes and other types of low-grade pCBCL. Benign, reactive processes do not have monotypic restriction of immunoglobulin light chain expression, in contrast to what is observed in the great majority of cases of PCMZLD. PCFCL, diffuse type, can be differentiated from PCMZLD by the architectural pattern and cytomorphology, with the former being characterized by a diffuse infiltrate of B lymphocytes with a predominance of centrocytes and centroblasts. Moreover, in contrast to PCMZLD, neoplastic cells in PCFCL express Bcl-6.

PCMZLD should also be distinguished from secondary cutaneous lesions of B cell chronic lymphocytic leukemia (B-CLL), a condition in which neoplastic B lymphocytes display positivity for CD20, CD23 and CD43, and usually for CD5. Helpful diagnostic features are: (1) the absence, in B-CLL, of plasma cells belonging to the neoplastic clone; and (2) the positivity for CD5 observed in most cases of cutaneous B-CLL, but practically never in PCMZLD. $CD20^+/CD5^+$ infiltrates are also seen in secondary skin involvement from mantle cell lymphoma, but in contrast to CLL, mantle cell lymphoma is usually positive for cyclin D1 and negative for CD23 (rare cases of mantle cell lymphoma that are negative for cyclin D1 are positive for SOX11).

PCMZLD with prominent plasma cell differentiation must be differentiated from reactive plasma cell proliferations and from inflammatory pseudotumors (plasma cell granulomas). In reactive conditions, plasma cells are not atypical, and they display a polyclonal pattern of immunoglobulin light chain expression. Besides inflammatory pseudotumors,

Downloaded for Anonymous User (n/a) at Egyptian Knowledge Bank from ClinicalKey.com by Elsevier on March 10, 2024. For personal use only. No other uses without permission. Copyright ©2024. Elsevier Inc. All rights reserved.

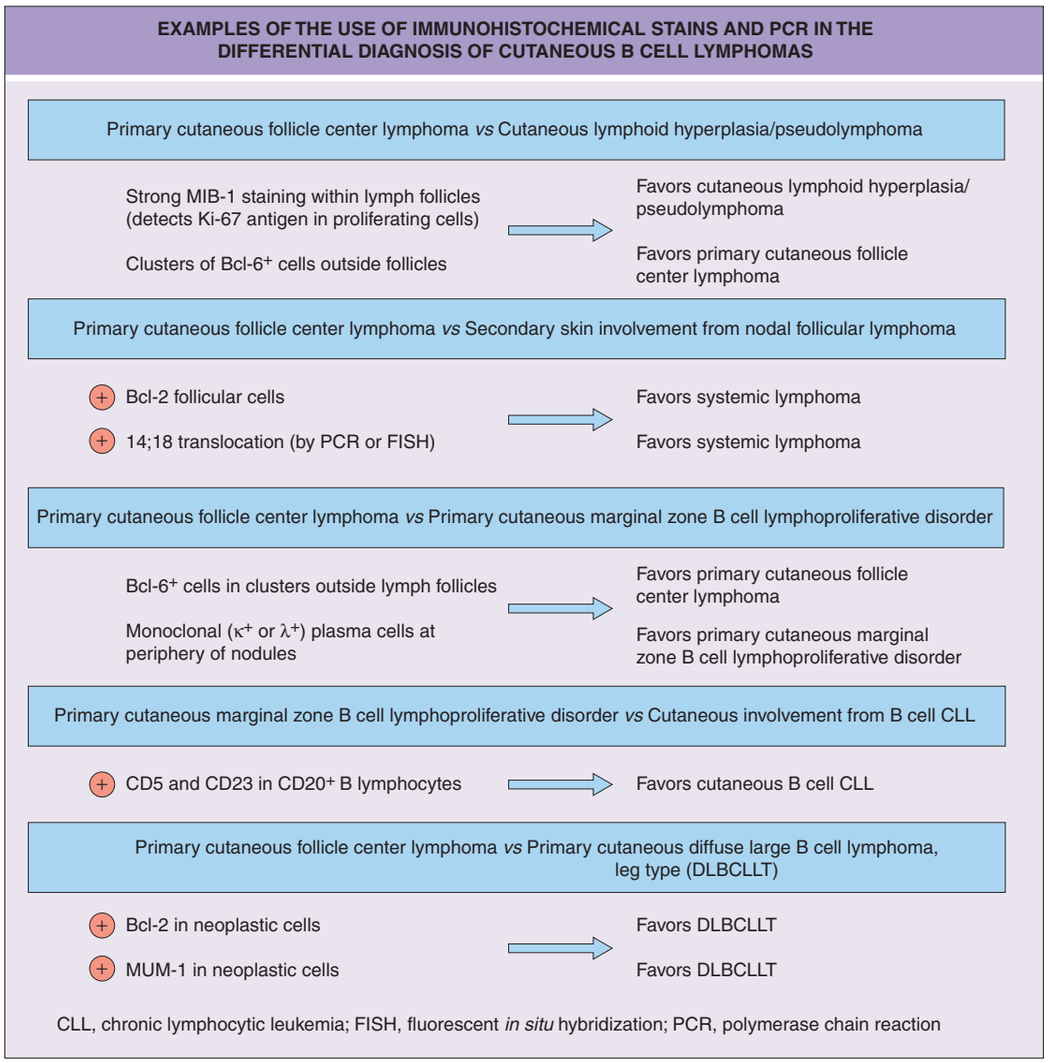

Fig. 119.16 Examples of the use of immunohistochemical stains and PCR in the differential diagnosis of cutaneous B cell lymphomas. This represents a simplification and is intended to assist dermatologists in their interpretation of pathology reports. CD20$^+$/CD5$^+$ infiltrates are also seen in secondary skin involvement from mantle cell lymphoma, but in contrast to CLL, mantle cell lymphoma is also positive for cyclin D1 and negative for CD23 (see Table 119.3).

reactive skin diseases with a predominance of plasma cells are very rare, with the exception of lesions arising on mucosal surfaces, spirochetal infections (e.g. syphilis, pinta, yaws, acrodermatitis chronica atrophicans), and cutaneous and systemic plasmacytosis. The latter disorder usually displays a polyclonal pattern of immunoglobulin light chain expression, but rarely monoclonality has been reported[38]. A silver stain (e.g. Warthin–Starry) or immunohistochemical staining for *Treponema pallidum* can help to highlight the microorganisms in cases of syphilis (see Fig. 0.33). The rare entity *pretibial lymphoplasmacytic plaque in children* is characterized by a polyclonal pattern of the plasma cells.

DLBCLLT must be differentiated from a number of entities, including cutaneous involvement from systemic lymphomas as well as specific infiltrates of acute myelogenous leukemia and non-lymphoid tumors (e.g. solid organ metastases; see Ch. 122). The clinicopathologic pattern together with phenotypic and molecular features allow correct classification of these lesions in most instances. In order to avoid diagnostic errors, detailed immunophenotyping is mandatory in all cases of cutaneous lymphoma, especially in those showing medium- to large-sized cell morphology.

The differential diagnosis of **IVDLBCL** is not a problem in typical cases. The large number of atypical cells within *blood vessels* is pathognomonic of this condition. Distinction between T and B cell types cannot be achieved on morphologic grounds alone. Rare cases of intralymphatic anaplastic large T cell lymphoma (ALCL) are characterized by a proliferation of neoplastic CD30$^+$ T cells within *lymphatic vessels*. This disorder represents a variant of ALCL and has similar phenotypic and prognostic features[39]. IVDLBCL should also be distinguished from reactive disorders characterized by an intravascular proliferation of atypical cells, in particular intralymphatic histiocytosis (IH) and benign intralymphatic proliferation of T cell lymphoid blasts (BIPTCLB). IH occurs in association with systemic disorders such as rheumatoid arthritis as well as metallic orthopedic implants. Within the dermis, *lymphatic vessels* that stain positively for podoplanin contain intraluminal collections of histiocytes (CD68$^+$, CD20$^-$, CD3$^-$). Of note, focal areas of IH can be an incidental finding. BIPTCLB is a rare entity observed in a wide range of cutaneous and extracutaneous disorders from pyogenic granuloma to appendicitis. As in IH, the *lymphatic vessels* are affected.

Cases of **precursor B lymphoblastic lymphoma/leukemia** should be differentiated from other cutaneous lymphomas/leukemias and from non-lymphoid tumors such as Ewing sarcoma, Merkel cell carcinoma, and small cell lung carcinoma. Positivity for TdT represents the most important immunohistochemical feature for the diagnosis of cutaneous lymphoblastic lymphoma. Histologic features of cutaneous lesions do not allow the differentiation of T cell from B cell lymphoblastic lymphomas, thus emphasizing the importance of complete immunophenotypic and genotypic analyses.

In immunosuppressed patients, the possibility of post-transplant lymphoproliferative disorder should be considered (Table 119.4).

TREATMENT

The most appropriate treatment modality for patients with a pCBCL is selected after exact classification of the lymphoma, analysis of results of staging investigations, and consideration of the overall condition of the patient[4]. Those patients with secondary cutaneous lesions of extracutaneous B cell lymphoma should be treated in a hemato-oncologic, not dermatologic, setting[4].

Before reviewing the major therapeutic strategies, it must be emphasized that many patients with low-grade pCBCL can be managed

Downloaded for Anonymous User (n/a) at Egyptian Knowledge Bank from ClinicalKey.com by Elsevier on March 10, 2024. For personal use only. No other uses without permission. Copyright ©2024. Elsevier Inc. All rights reserved.

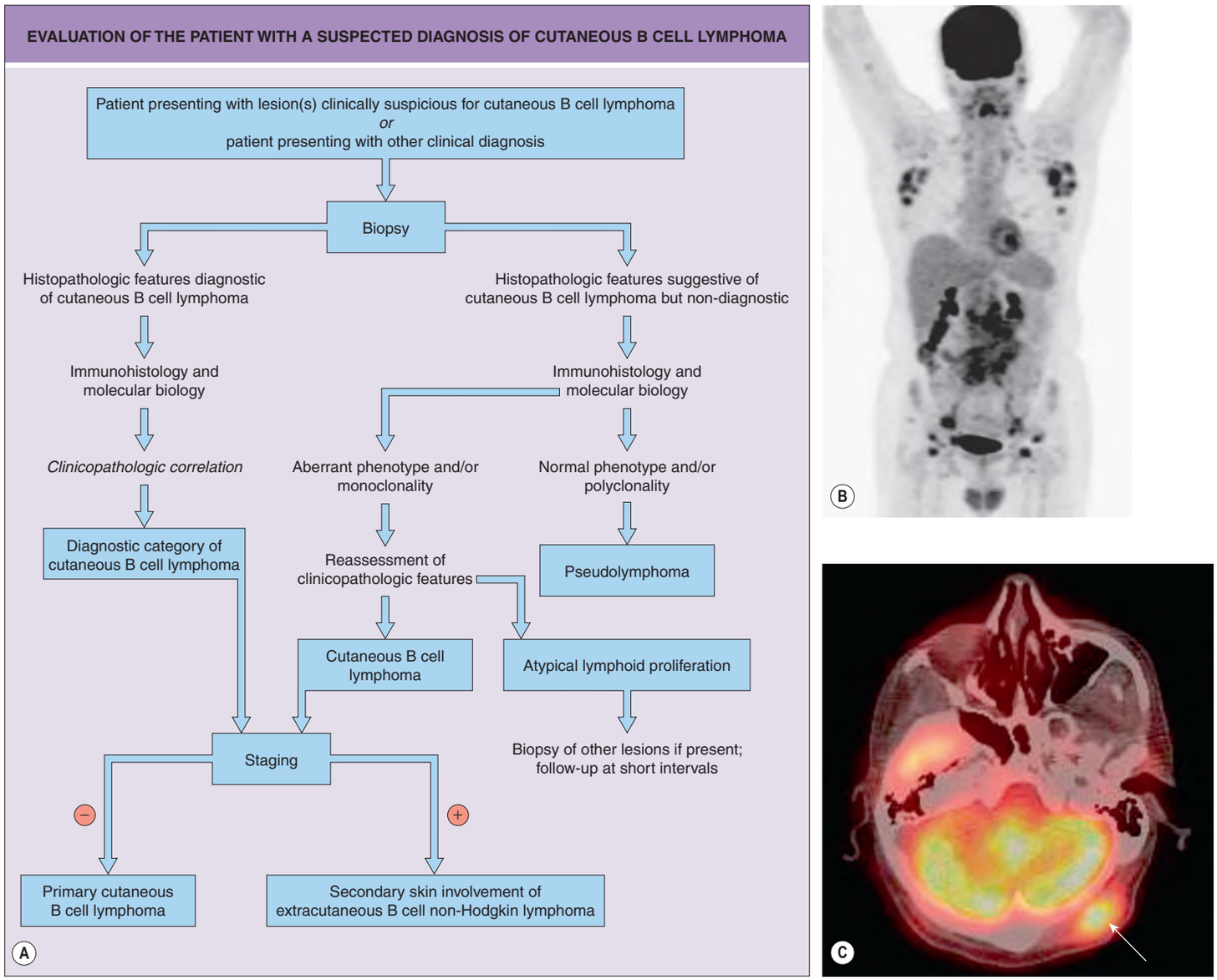

Fig. 119.17 Evaluation of the patient with a suspected diagnosis of cutaneous B cell lymphoma. A Algorithm outlining approach to the patient. **B, C** Positron emission tomography (PET) scans in a 66-year-old patient with stage IV B cell non-Hodgkin lymphoma. He had a 1-year history of a cutaneous nodule of the scalp that was originally diagnosed as an epidermoid inclusion cyst. Biopsy of the nodule showed a diffuse large B cell lymphoma ($CD10^+$, $CD20^+$, variably $Bcl\text{-}2^+$, $MUM\text{-}1^-$) and a PET-CT scan was performed for staging. There is evidence of widespread disease involving multiple lymph node basins in the dedicated (MIP) image (**B**) as well as a scalp lesion in a PET-CT fusion image (**C**; arrow). *B,C, Courtesy Dennis Cooper, MD.*

POST-TRANSPLANT LYMPHOPROLIFERATIVE DISORDERS
• Arise in the setting of immunosuppression
• Most commonly seen in solid organ transplant recipients, but can also affect other chronically immunosuppressed hosts (e.g. patient with rheumatoid arthritis receiving chronic methotrexate, HIV-positive patient)
• Patients most commonly present with extranodal disease, often involving the transplanted organ
• Other common sites of involvement include the GI tract and skin
• In the skin, polymorphic or monomorphic infiltrates are seen with the latter having similar clinicopathologic findings as conventional cutaneous B and NK/T cell lymphomas
• The abnormal lymphocytes are often EBV-positive, especially if B cells
• Initial therapeutic intervention is reduction of immunosuppression
• If persistent disease, appropriate treatment is administered depending on cell type

Table 119.4 Post-transplant lymphoproliferative disorders. EBV, Epstein–Barr virus; GI, gastrointestinal.

conservatively with a so-called watchful-waiting strategy, similar to what is often adopted for indolent B cell lymphomas and leukemias at extracutaneous sites[4,40]. Follow-up examinations in these patients should be performed at least every 6 months or at the onset of new lesions and/or new symptoms, in order to treat the patient as soon as it is necessary. Many patients managed conservatively with a watchful-waiting strategy experience a prolonged course and long survival, and they do not need aggressive treatment. For cosmesis and sometimes psychological benefit, intralesional triamcinolone can be injected into the papulonodules.

Most patients with pCBCLs that are low-grade (PCFCL, PCMZLD) and who have a solitary or few lesions can be treated by local radiotherapy, simple surgical excision, or surgical excision followed by radiotherapy of the surgical field[4,40]. It has been reported that recurrences are less frequently seen in patients treated by radiotherapy with wide margins (about 10–20 cm beyond clinically apparent lesions); this approach seems to be justified for so-called Crosti's lymphoma, a type of PCFCL arising on the back, in which erythematous nodules, papules, and patches surrounding the tumor represent specific infiltrates that can extend far beyond the main bulk of the lesion[41]. Radiotherapy with wide margins, however, does not seem to be justified for lesions other

Downloaded for Anonymous User (n/a) at Egyptian Knowledge Bank from ClinicalKey.com by Elsevier on March 10, 2024. For personal use only. No other uses without permission. Copyright ©2024. Elsevier Inc. All rights reserved.

than Crosti's lymphoma, as margins of about 3–5 cm usually suffice (depending on the size of the lesion). Surgical excision with narrow margins is a valuable therapeutic modality for patients with solitary well-circumscribed lesions and in the authors' opinion represents the treatment of choice for PCMZLD. In these patients, relapse rates do not seem to be higher than in patients treated with more time-intensive modalities such as local radiotherapy.

A few reports have appeared in which low-grade pCBCLs were treated with systemic antibiotics, achieving a complete resolution in at least a percentage of the patients[42]. This type of treatment is conceptually analogous to that adopted for *Helicobacter pylori*-associated MALT lymphomas of the stomach, which in their early stages can be cured by eradication of *H. pylori* infection. Complete response to antibiotic therapy has been observed in some patients with *Borrelia*-associated pCBCL. Although not yet corroborated by adequate data, antibiotic treatment of patients with pCBCLs should be considered before more aggressive therapeutic options are employed, particularly in European countries endemic for *Borrelia* infections. It is important to treat patients at the onset of the disease, because, in later stages, lesions may no longer be sensitive to systemic antibiotics. PCR analysis of *Borrelia* DNA is a rapid test that should be performed in all patients with pCBCL from European endemic areas, in order to identify those who would more likely benefit from early antibiotic treatment.

Another treatment modality for low-grade pCBCL is subcutaneous or intralesional interferon, particularly interferon-α-2a. Although some favorable results have been reported, it appears that treatment with interferon is associated with a complete response in about 50% of patients. Therapy with interferon (or intralesional triamcinolone) should be considered for patients presenting with multiple lesions at different body sites, such that local radiotherapy becomes difficult to administer.

Intralesional or systemic injection of anti-CD20 monoclonal antibody (rituximab) has been used to induce tumor reduction in patients with indolent pCBCLs[43,44]. Intralesional administration should be considered in patients presenting with a few, localized lesions. Therapy with intravenous rituximab represents a valid alternative to established treatments, especially in patients who present with disseminated skin lesions or relapse after radiotherapy. Rituximab can also be administered in combination with other treatment modalities for pCBCLs with more aggressive behavior (e.g. DLBCLLT). Additional monoclonal antibodies, bispecific T-cell engaging antibodies (e.g. mosunetuzumab), and small-molecule inhibitors (e.g. ibrutinib, lenalidomide) are also employed for aggressive B-cell lymphomas.

Patients with DLBCLLT and a limited number of patients with disseminated lesions of PCFCL, diffuse type, need more aggressive treatment modalities (e.g. systemic chemotherapy plus rituximab)[40,45]. The regimen used most frequently is cyclophosphamide, doxorubicin, vincristine and prednisone (CHOP) plus rituximab, and it represents the standard of care for DLBCLLT. In the absence of signs of transformation into high-grade lymphoma, aggressive treatment is not indicated in patients with PCMZLD. In the setting of significant comorbidities, rituximab alone or in combination with local radiotherapy may be administered. For relapsed DLBCLLT, CAR-T cell therapy is increasingly being used, especially when recurrence occurs within one year of primary therapy. In the setting of longer remissions, salvage chemotherapy followed by autologous HSCT is an option.

Systemic chemotherapy plus rituximab is the treatment of choice for patients with IVDLBCL, regardless of results of staging investigations. As with DLBCLLT, the addition of rituximab to anthracycline-based chemotherapy significantly improves outcome[45]. Finally, patients with precursor B lymphoblastic lymphoma/leukemia should be treated as B cell acute lymphoblastic leukemia by a hematologist.

PLASMA CELL DYSCRASIAS, INCLUDING MULTIPLE MYELOMA

A plasma cell dyscrasia represents a clonal proliferation of plasma cells and it can lead to a monoclonal gammopathy composed of intact immunoglobulins, isolated light chains (15% of patients) or, rarely, isolated heavy chains. The term plasma cell dyscrasia encompasses a number of entities, including monoclonal gammopathy of undetermined significance (MGUS; serum paraprotein <3 g/dl), smoldering/asymptomatic myeloma, and active/symptomatic myeloma, as well as light and heavy chain deposition diseases and systemic amyloidosis (AL). While proliferations of plasma cells within the skin are rare, an understanding of the spectrum and natural history of plasma cell dyscrasias is important for dermatologists given the number of cutaneous disorders associated with monoclonal gammopathies (Table 119.5; Fig. 119.18).

CUTANEOUS CONDITIONS ASSOCIATED WITH MONOCLONAL GAMMOPATHY
Proliferation of lymphoplasmacytic cells in the skin
• Extramedullary cutaneous plasmacytoma*
• Cutaneous Waldenström macroglobulinemia†
Deposition of the monoclonal protein in the skin, by definition
• Primary systemic amyloidosis (light chains)
• Cryoglobulinemic occlusive vasculopathy (type I cryoglobulins‡)
• Hyperkeratotic spicules (follicular > non-follicular)
• Crystal-storing histiocytosis
• Crystalglobulinemia
• IgM storage papules (cutaneous macroglobulinosis)†
• Subepidermal bullous dermatosis associated with IgM gammopathy†
Deposition of the monoclonal protein in the skin frequently observed
• Plasma cell dyscrasia-associated acquired cutis laxa, acral or generalized (amyloid and/or IgG)
• Plasma cell dyscrasia-associated reactive angioendotheliomatosis (type I cryoglobulins or amyloid)
Almost always associated with monoclonal gammopathy
• Scleromyxedema
• POEMS syndrome¶
• AESOP syndrome – *a*denopathy and *e*xtensive skin patch *o*verlying a *p*lasmacytoma; may coexist with POEMS syndrome¶
• TEMPI syndrome – *t*elangiectasias, *e*levated erythropoietin and erythrocytosis, *m*onoclonal gammopathy, *p*erinephric fluid collection, and *i*ntrapulmonary shunting
• Schnitzler syndrome†
• Necrobiotic xanthogranuloma
Frequently associated with monoclonal gammopathy
• Normolipemic plane xanthoma
• Scleredema (type 2)
• Angioedema secondary to acquired C1 esterase inhibitor deficiency
• Idiopathic systemic capillary leak syndrome (Clarkson syndrome)
Significant association with monoclonal gammopathy, primarily IgA (at least 15% of cases)
• Erythema elevatum diutinum
• Subcorneal pustular dermatosis (SPD) and SPD-type IgA pemphigus
• Pyoderma gangrenosum
• Neutrophilic papular xanthoma
Occasionally associated with monoclonal gammopathy
• Sweet syndrome
• Cutaneous small vessel vasculitis‡, including adult IgA vasculitis with monoclonal IgA gammopathy
• Xanthoma disseminatum
• Epidermolysis bullosa acquisita
• Paraneoplastic pemphigus
• Atypical scleroderma§

*In the current IC 2022 classification (see Table 119.1), primary cutaneous plasmacytoma is classified as primary cutaneous marginal zone B cell lymphoproliferative disorder.
†IgM monoclonal gammopathy is present by definition; in Schnitzler syndrome, IgG gammopathy has occasionally been observed; Waldenström macroglobulinemia is due to a lymphoplasmacytic lymphoma.
‡Cryoglobulinemic vasculitis can occur secondary to type II cryoglobulins.
¶Polyneuropathy (P), organomegaly (O), endocrinopathy (E), M-protein (M), skin changes (S; see Ch. 53 for list of skin changes); diagnosis requires monoclonal plasmaproliferative disorder & neuropathy + one other major criterion (sclerotic bone lesions, Castleman disease, increased serum VEGF levels) and one minor criterion (extravascular volume overload, papilledema, O, E, S, thrombocytosis/polycythemia).
§Possible association; sclerodermoid changes can also occur in the setting of primary systemic amyloidosis.

Table 119.5 Cutaneous conditions associated with monoclonal gammopathy. In some entities, there is a predominance of one type of immunoglobulin light chain, e.g. λ in scleromyxedema, κ in necrobiotic xanthogranuloma.

Downloaded for Anonymous User (n/a) at Egyptian Knowledge Bank from ClinicalKey.com by Elsevier on March 10, 2024. For personal use only. No other uses without permission. Copyright ©2024. Elsevier Inc. All rights reserved.

Fig. 119.18 Disorders associated with a monoclonal gammopathy. Subcorneal pustular dermatosis characterized by superficial vesiculopustules arising within a background of erythema; the patient had an IgA kappa monoclonal gammopathy. The clinical differential diagnosis includes IgA pemphigus. *Courtesy Karynne O. Duncan, MD.*

The diagnosis of symptomatic myeloma has recently been broadened from the need for disease-related CRAB (*c*alcium elevation, *r*enal insufficiency, *a*nemia and/or *b*one lesions [osteolytic > osteosclerotic]) to include patients with ≥60% bone marrow plasmacytosis, >1 lytic lesion on total body MRI (or PET-CT), or a ratio of involved : uninvolved free light chains of ≥100 : 1.

Of note, the level of circulating monoclonal protein associated with several of the skin disorders listed in Table 119.5 may be so low as to fall below the detection limit of a serum protein electrophoresis or an IgA paraprotein may not be detected because it falls within and is obscured by the β band. As a result, the more sensitive serum immunofixation electrophoresis (IFE) is required to detect an intact immunoglobulin (e.g. IgG, IgA) paraprotein.

In diagnosing patients with systemic amyloidosis whose cutaneous amyloid deposits are composed of light chains, the serum free light chain (SFLC) ratio is much more sensitive than even the serum IFE. In addition, because light chains are rapidly excreted into the urine, a urine IFE in addition to SFLC assay is necessary to exclude a light chain-producing plasma cell dyscrasia.

Histopathology

In specific skin lesions (see Table 119.5), diffuse infiltration of the dermis by atypical plasma cells or lymphoplasmacytoid cells is present, usually with several mitoses. Multinucleated plasma cells may be found. The infiltrating cells can be difficult to recognize as plasma cells, and CD45 and CD20 are negative in the vast majority of cases. Neoplastic plasma cells can be stained with CD38 and CD138, and they express monotypic immunoglobulins. Intracytoplasmic eosinophilic inclusions (Russell bodies) are often present; the cells are called Mott cells when these bodies form grape-like clusters. PAS-positive eosinophilic inclusions in the nucleus (Dutcher bodies) can also be observed. These are thought to be immunoglobulin or glycoprotein accumulations, and they can be found in other neoplastic conditions in which plasma cells are prevalent (e.g. plasma cell-rich PCMZLD; see Fig. 119.9B).

Differential Diagnosis

The differential diagnosis of PCMZLD with prominent plasma cell differentiation (formerly called cutaneous plasmacytoma) is discussed above. Cutaneous Waldenström macroglobulinemia has histologic features similar to PCMZLD with prominent lymphoplasmacytic differentiation (formerly called cutaneous immunocytoma)[46], except that direct immunofluorescence demonstrates monoclonal IgM within and around the infiltrating cells. Immunofixation electrophoresis of the serum detects the circulating monoclonal protein as IgM.

CUTANEOUS AND SYSTEMIC PLASMACYTOSIS

In cutaneous and systemic plasmacytosis, an entity most commonly seen in Asians, red–brown to violet–brown papules or nodules favor the back but can be widely disseminated[38]. Patients with the systemic form also have lymphadenopathy and occasionally have involvement of the lung, liver, spleen, or kidneys. The associated hypergammaglobulinemia is polyclonal as are the infiltrating plasma cells. Histologically, there are variably large aggregates of polyclonal plasma cells in the dermis, usually admixed with an inflammatory infiltrate and sometimes with reactive germinal centers[38]. The findings may overlap with those of plasma cell-rich Castleman disease.

Additional figures available in our eBook (see inside front cover for access code).

eFig. 119.1 Cutaneous follicle center lymphoma. Prominent pink–violet nodule on the lateral forehead with a few telangiectasias. The nodule is surrounded by papules and large infiltrated plaques.

eFig. 119.2 Cutaneous follicle center lymphoma. Large ulcerated tumors on the scalp surrounded by infiltrated erythematous nodules and plaques.

eFig. 119.3 Cutaneous follicle center lymphoma. Large ulcerated tumor on the back. Note surrounding erythematous papules, patches, and plaques (Crosti's lymphoma).

eFig. 119.4 Cutaneous marginal zone B cell lymphoproliferative disorder. Two well-circumscribed, erythematous nodules on the shoulder.

eFig. 119.5 Cutaneous marginal zone B cell lymphoproliferative disorder. Dome-shaped erythematous nodule with smooth surface. The surrounding area shows features of acrodermatitis chronica atrophicans. This tumor, which demonstrated prominent lymphoplasmacytic differentiation histologically, would have been classified as cutaneous immunocytoma in the past.

Downloaded for Anonymous User (n/a) at Egyptian Knowledge Bank from ClinicalKey.com by Elsevier on March 10, 2024. For personal use only. No other uses without permission. Copyright ©2024. Elsevier Inc. All rights reserved.

eFig. 119.6 Cutaneous diffuse large B cell lymphoma, leg type. Multiple red–brown tumors on the lower leg.

eFig. 119.8 Cutaneous diffuse large B cell lymphoma, leg type. Multiple red–brown papulonodules and a tumor on the lower leg.

eFig. 119.7 Cutaneous diffuse large B cell lymphoma, leg type. Multiple coalescing red–brown papulonodules and plaques on the lower leg.

eFig. 119.9 Precursor B lymphoblastic lymphoma/leukemia. Large erythematous tumor on the face of a small child.

Downloaded for Anonymous User (n/a) at Egyptian Knowledge Bank from ClinicalKey.com by Elsevier on March 10, 2024. For personal use only. No other uses without permission. Copyright ©2024. Elsevier Inc. All rights reserved.

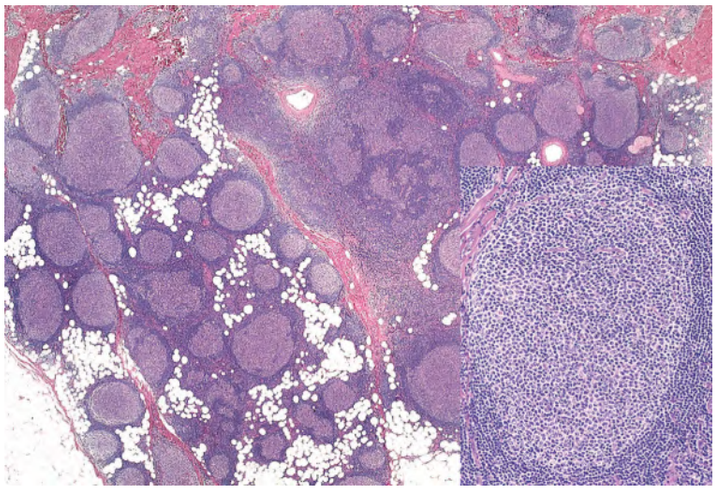

eFig. 119.10 Cutaneous follicle center lymphoma, follicular type. Neoplastic follicles with a monomorphous morphology (lack of polarization). Note the absence of dark and clear areas within the central portion of the follicle (inset).

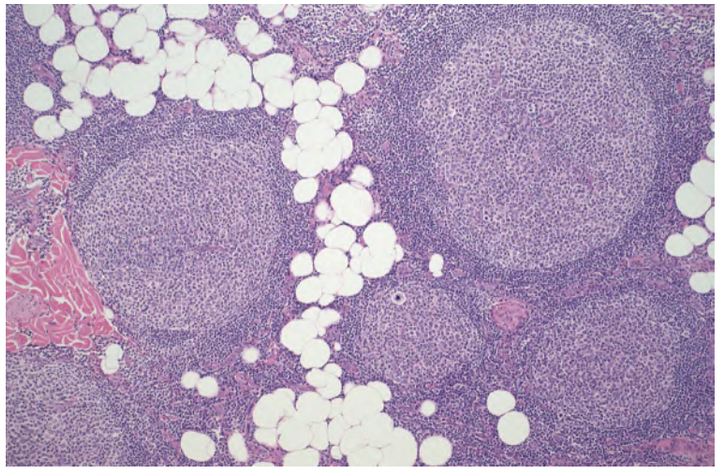

eFig. 119.11 Cutaneous follicle center lymphoma, follicular type. Neoplastic follicles with monomorphous morphology.

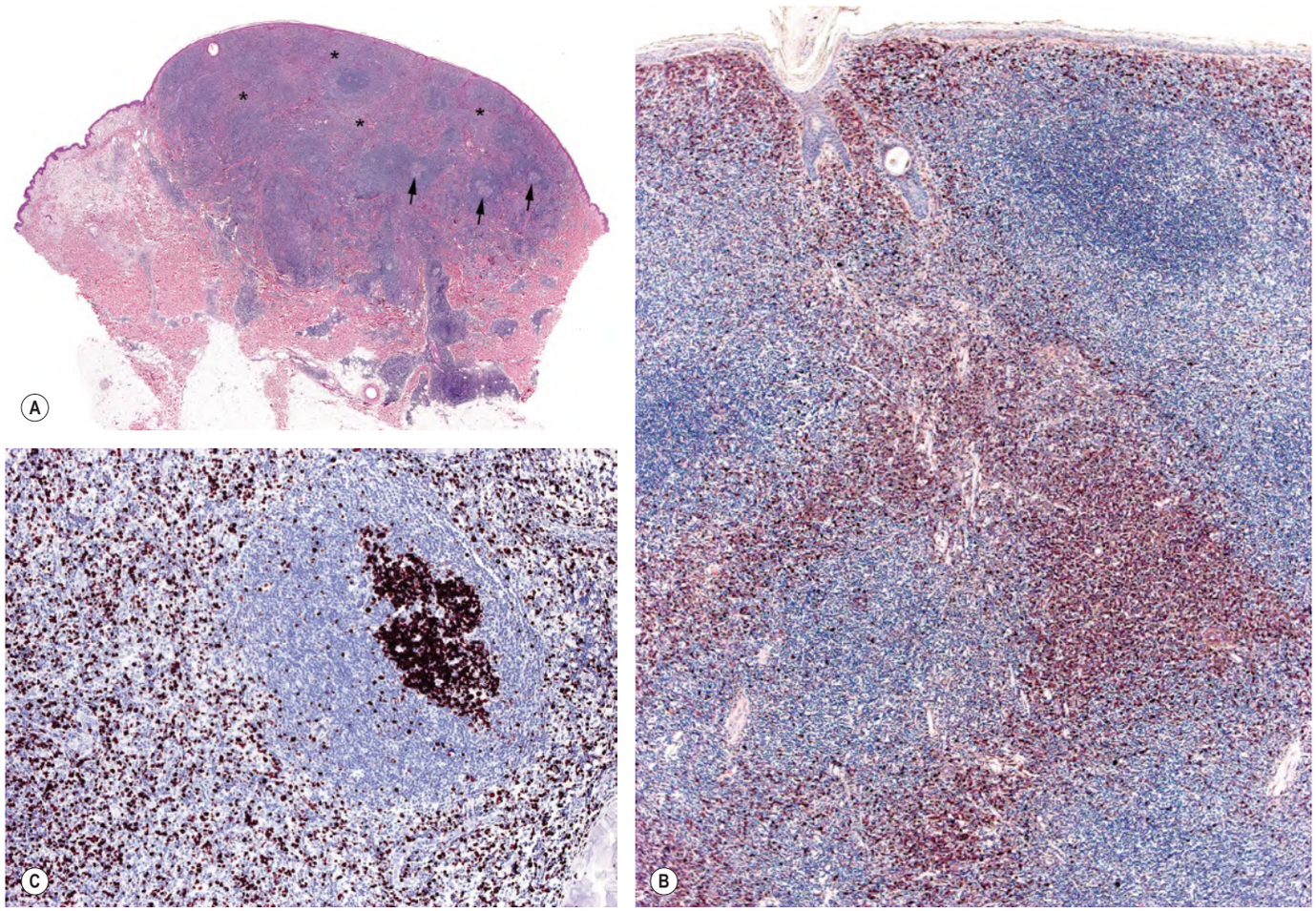

eFig. 119.12 Cutaneous marginal zone B cell lymphoproliferative disorder. A Small nodules of *reactive* lymphocytes (dark areas), some of which have reactive germinal centers (arrows). The nodules are surrounded by *neoplastic* marginal zone cells, lymphoplasmacytoid cells, and plasma cells (clear areas [*]). **B** Monotypic expression of λ immunoglobulin light chain within the neoplastic population of cells (in the clear areas). **C** MIB-1 staining shows marked proliferation within a germinal center in a reactive lymphoid follicle and increased proliferation of neoplastic cells in the perifollicular area.

Downloaded for Anonymous User (n/a) at Egyptian Knowledge Bank from ClinicalKey.com by Elsevier on March 10, 2024. For personal use only. No other uses without permission. Copyright ©2024. Elsevier Inc. All rights reserved.

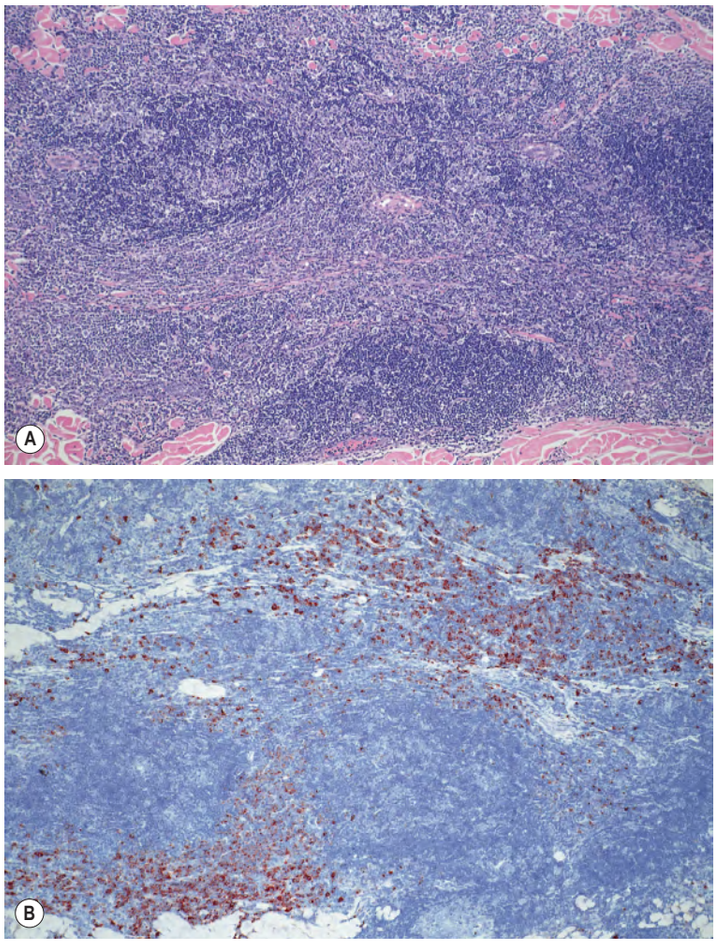

eFig. 119.13 Cutaneous marginal zone B cell lymphoproliferative disorder. **A** Small nodules of reactive lymphocytes (dark areas) surrounded by neoplastic marginal zone cells, lymphoplasmacytoid cells and plasma cells (clear areas). **B** Monotypic expression of λ immunoglobulin light chain within the neoplastic population of cells.

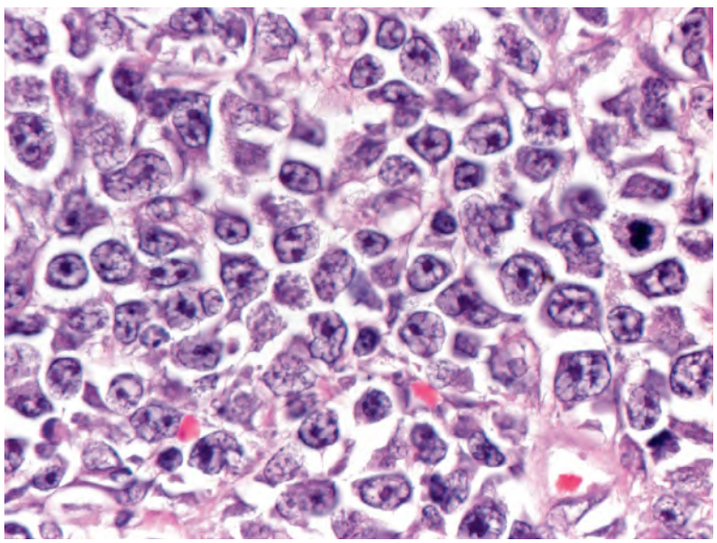

eFig. 119.14 Cutaneous diffuse large B cell lymphoma, leg type. Large cells with a round morphology (mainly immunoblasts) predominate.

Downloaded for Anonymous User (n/a) at Egyptian Knowledge Bank from ClinicalKey.com by Elsevier on March 10, 2024. For personal use only. No other uses without permission. Copyright ©2024. Elsevier Inc. All rights reserved.

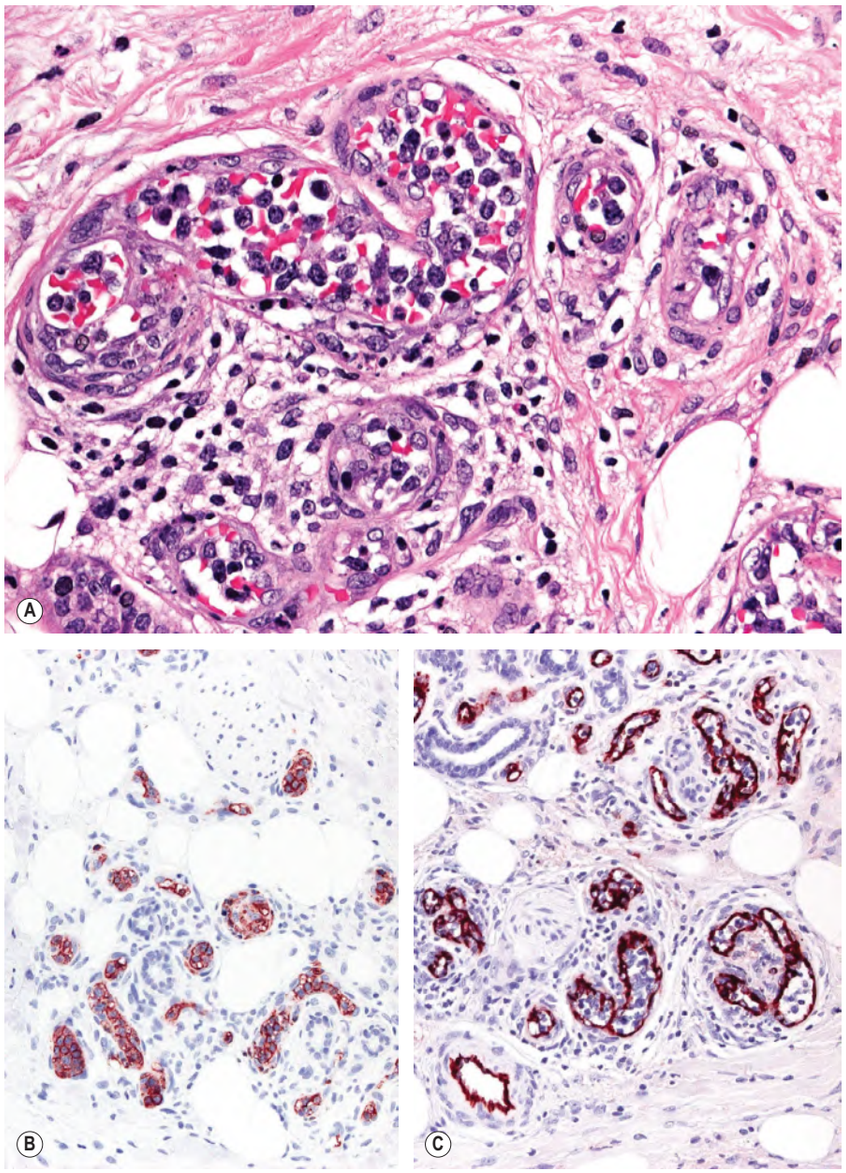

eFig. 119.15 Cutaneous diffuse intravascular large B cell lymphoma. A Intravascular proliferation of medium- to large-sized atypical lymphocytes. **B** Positive immunohistochemical staining of neoplastic cells for CD20. **C** Intravascular location of neoplastic cells highlighted by staining for endothelial cells (CD31).

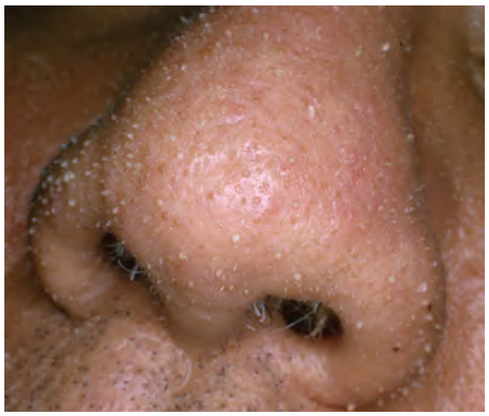

eFig. 119.16 Follicular spicules in a patient with multiple myeloma. *Courtesy Irwin Braverman, MD.*

eFig. 119.17 Plasmacytosis – cutaneous involvement. Multiple violet–brown oval-shaped plaques on the back. *Courtesy Boni Elewski, MD.*

Downloaded for Anonymous User (n/a) at Egyptian Knowledge Bank from ClinicalKey.com by Elsevier on March 10, 2024. For personal use only. No other uses without permission. Copyright ©2024. Elsevier Inc. All rights reserved.